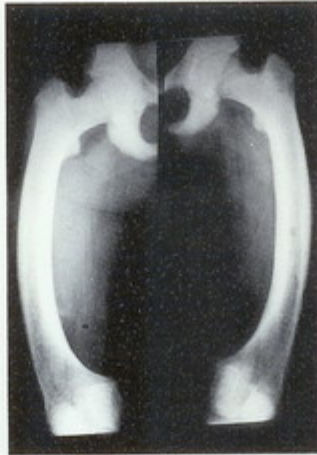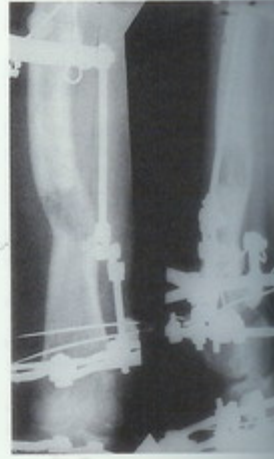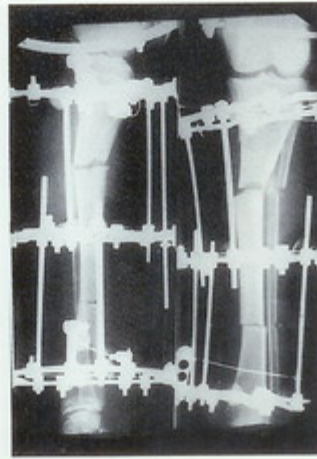
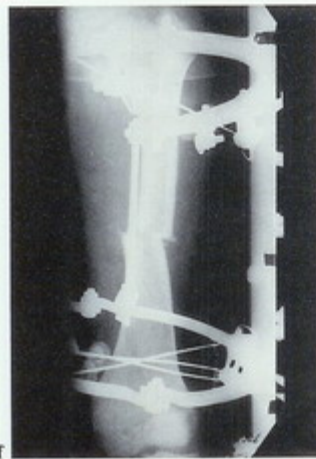


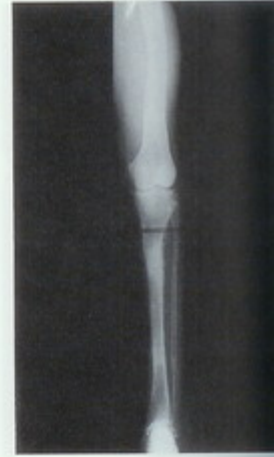
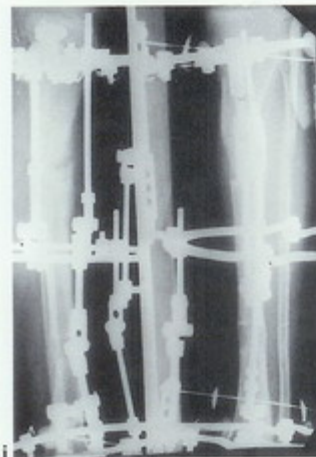
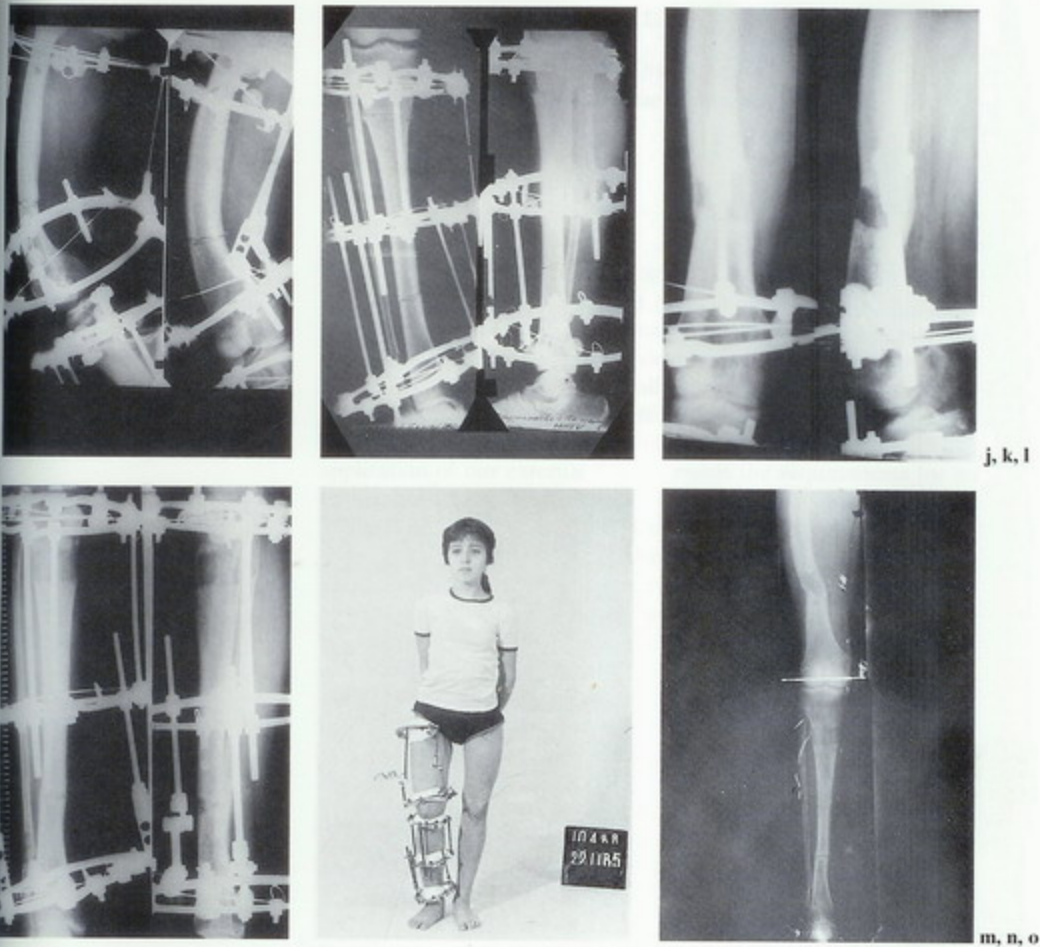
a, b, c



d, e, f



g, h, i



**Fig. 7.35 a-p**

A 16-year-old female patient with deformities of all four lower limb segments

- a The patient before treatment
- b Roentgenograms of the femora before treatment
- c Roentgenograms of the lower legs before treatment
- d The left femur in a fixator after compactotomy at one level
- e The left tibia in a fixator after compactotomy at two levels
- f Roentgenograms after correction of the deformity of the left femur
- g Roentgenograms after correction of the deformity of the left tibia

- h The patient during treatment
- i Roentgenogram after removal of the apparatus
- j The right femur after compactotomy
- k The right tibia after two-level compactotomy
- l Roentgenograms after correction of the right femoral deformity
- m Roentgenograms after correction of the right tibial deformity
- n The patient during treatment
- o Roentgenogram after removal of the apparatus
- p The patient after treatment