

THE JOURNAL OF BONE & JOINT SURGERY

J B & J S

This is an enhanced PDF from The Journal of Bone and Joint Surgery

The PDF of the article you requested follows this cover page.

Calcaneal lengthening for valgus deformity of the hindfoot. Results in children who had severe, symptomatic flatfoot and skewfoot

VS Mosca

J Bone Joint Surg Am. 1995;77:500-512.

This information is current as of November 19, 2007

Reprints and Permissions

Click here to [order reprints or request permission](#) to use material from this article, or locate the article citation on jbjs.org and click on the [Reprints and Permissions] link.

Publisher Information

The Journal of Bone and Joint Surgery
20 Pickering Street, Needham, MA 02492-3157
www.jbjs.org

Calcaneal Lengthening for Valgus Deformity of the Hindfoot

RESULTS IN CHILDREN WHO HAD SEVERE, SYMPTOMATIC FLATFOOT AND SKEWFOOT*

BY VINCENT S. MOSCA, M.D.†, SEATTLE, WASHINGTON

Investigation performed at the Department of Orthopedics, Children's Hospital and Medical Center, Seattle

ABSTRACT: Thirty-one severe, symptomatic valgus deformities of the hindfoot in twenty children who had flatfoot (twenty-five feet) or skewfoot (six feet) were corrected with a modification of the calcaneal lengthening osteotomy described by Evans. Despite prolonged non-operative treatment, all patients had pain, a callus, ulceration, or a combination of these signs and symptoms under the head of the plantar flexed talus; they could not tolerate a brace, and shoe wear was excessive. Twenty-six of the deformities were secondary to an underlying neuromuscular disorder. The calcaneal lengthening was combined with an opening-wedge osteotomy of the medial cuneiform to correct the deformities of both the hindfoot and the forefoot in the patients who had a skewfoot. Other concurrent osseous and soft-tissue procedures were frequently performed in the flatfeet and skewfeet to correct adjacent deformities or to balance the muscle forces. Allograft bone was used in twenty-four feet and autogenous bone, in seven. The patients ranged in age from four years and seven months to sixteen years at the time of the operation. The duration of follow-up ranged from two years to three years and seven months after the operation.

Satisfactory clinical and radiographic correction of all components of the deformity of the hindfoot was achieved in all but the two most severely deformed feet. These two feet had sufficient correction to eliminate the symptoms despite a small persistent callus under the head of the talus. The pain and callus were eliminated in all of the other feet, the patients were able to tolerate a brace, and shoe wear was improved. Subtalar motion was preserved in all feet except for the four that had had a limited joint arthrodesis performed previously or simultaneously for pre-existing degenerative osteoarthritis.

Calcaneal lengthening is effective for the correction of severe, intractably symptomatic valgus deformities of the hindfoot in children. My patients had resolu-

tion of the signs and symptoms associated with the deformity while avoiding the need for an arthrodesis and the many short and long-term complications associated with it.

Valgus deformity of the hindfoot is a clinical description of the complex three-dimensional malalignment of the subtalar complex that occurs in flatfoot and skewfoot deformities. The alignment of the forefoot may be used to differentiate these two entities³⁰.

A flatfoot (Figs. 1-A, 1-B, 2-A, and 2-B) is characterized by plantar flexion of the talus and calcaneus along with excessive eversion of the subtalar complex during weight-bearing. There is valgus deformity, external rotation, and dorsiflexion of the calcaneus in relation to the talus. The navicular is abducted and dorsiflexed on the head of the plantar flexed talus. These combined relationships create a sag in the middle of the foot with lowering of the longitudinal arch. The lateral column (or border) of the foot is short relative to the medial column; this may be a true length discrepancy or it may be related to the lateral alignment at the talonavicular joint. The forefoot is supinated in relation to the hindfoot.

In a skewfoot (Figs. 3-A and 3-B), the same eversion of the subtalar complex with valgus deformity of the hindfoot is combined with adduction and plantar flexion of the forefoot on the midfoot. It is not known how much adduction and plantar flexion of the forefoot are necessary to differentiate a flatfoot from a skewfoot or, for that matter, how much valgus deformity of the hindfoot is required to differentiate a metatarsus adductus deformity from a skewfoot. There is, in fact, no consensus regarding the clinical or radiographic criteria (including age-related interosseous measurements) to define the forefoot and hindfoot relationships in flatfoot, skewfoot, and metatarsus adductus deformities. Despite the absence of specific criteria, treatment of these deformities can be reasonably undertaken on the basis of symptoms that correspond to clinical deformity and to abnormal findings on radiographs. Only a small percentage of any of these deformities of the foot cause disability.

Disability from flat and skewfeet is usually manifested by pain with weight-bearing, a callus, ulceration, or a combination of these signs and symptoms under

*No benefits in any form have been received or will be received from a commercial party related directly or indirectly to the subject of this article. No funds were received in support of this study.

†Department of Orthopedics, Children's Hospital and Medical Center, P.O. Box C5371, 4800 Sand Point Way N.E., Seattle, Washington 98105.

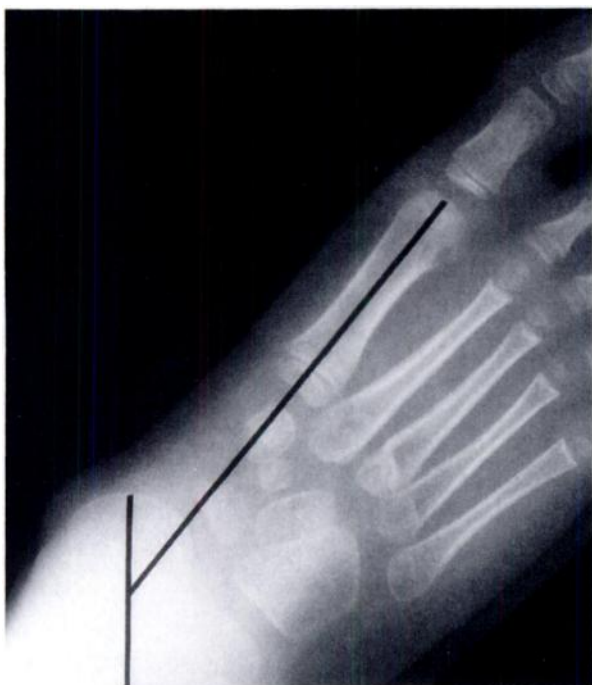

FIG. 1-A

Figs. 1-A through 1-D: A severe flatfoot that was corrected with calcaneal lengthening. The lines represent the axis of the talus and the axis of the first metatarsal.

Fig. 1-A: Preoperative anteroposterior radiograph showing abduction at the talonavicular joint, external rotation of the calcaneus in the subtalar joint, a short lateral column of the foot, and valgus deformity of the subtalar joint (an increased talocalcaneal angle).

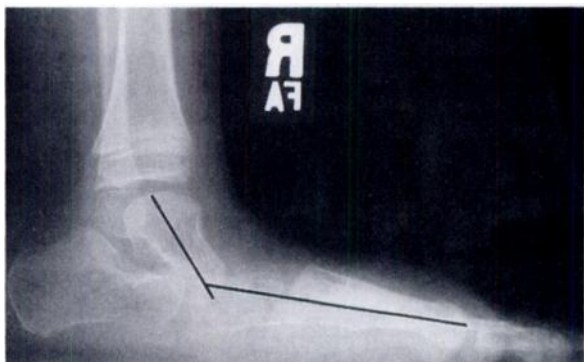


FIG. 1-B

Preoperative lateral radiograph showing dorsal alignment of the navicular on a plantar flexed talus, which, combined with plantar flexion of the calcaneus, creates a sag of the midfoot.

the head of the plantar flexed talus. Contracture of the Achilles tendon often accompanies symptomatic flat-foot^{34,35} and skewfeet, except in some patients who have myelomeningocele or poliomyelitis. A contracted Achilles tendon prevents normal dorsiflexion of the ankle during the mid-stance phase of the gait cycle. The dorsiflexion stress is shifted to the talonavicular joint. The soft tissues underlying the head of the rigidly plantar flexed talus are subjected to excessive direct axial loading and shear forces. These pressures are exaggerated by spastic muscles and by the use of hard plastic orthoses adjacent to the skin. Such pressures can lead to

breakdown of the skin in conditions such as myelomeningocele, in which insensate skin allows the patient to tolerate prolonged pressure over osseous prominences without pain.

Custom-molded and padded orthoses can often

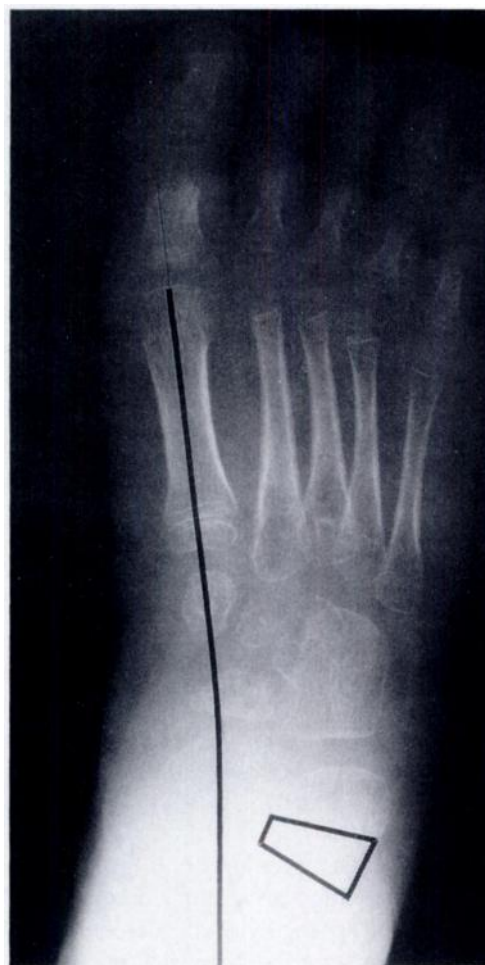

FIG. 1-C

Anteroposterior radiograph made after calcaneal lengthening, showing correction of the deformity. The box represents the size of the graft needed to correct the deformity.

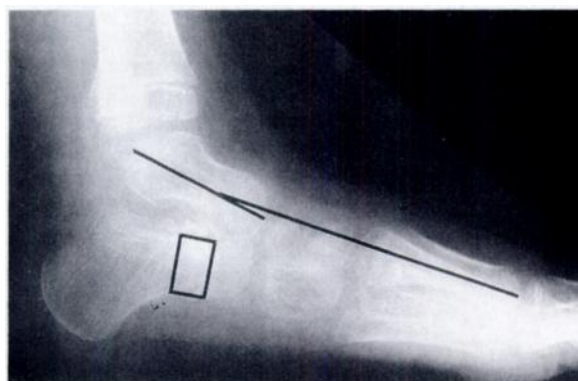


FIG. 1-D

Lateral radiograph made after calcaneal lengthening, showing correction of the deformity. The box represents the size of the graft needed to correct the deformity.

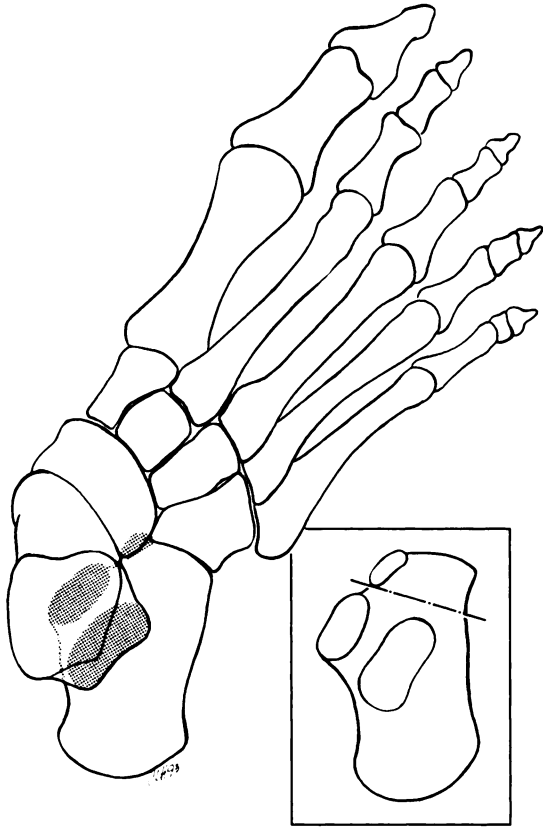


FIG. 2-A

Figs. 2-A through 2-D: Illustrations detailing the calcaneal lengthening for correction of valgus deformity of the hindfoot.

Fig. 2-A: Dorsal view of a flatfoot. There is abduction at the talonavicular joint. The oblique line of the osteotomy on the dorsal surface of the calcaneus exits medially between the anterior and middle facets (inset).

relieve symptomatic pressure points on flatfeet and skewfeet by inverting the subtalar complex and dorsiflexing the talus, especially if the deformities are supple. More rigid or severe deformities, particularly those associated with a short Achilles tendon, often lead to symptomatic intolerance of orthoses and rapid destruction of shoes. An operation is indicated when prolonged non-operative treatment fails to relieve pain, a callus, or ulceration under the head of the talus.

Most operative procedures to correct valgus deformities of the hindfoot involve arthrodesis of single or multiple joints. Although most of these procedures have led to successful short-term results, all long-term follow-up studies have shown that arthrodesis of any joint or

joints in the foot of a child leads to early degenerative changes at adjacent joints^{1,3,9,14,18,20,37,57,63,66,68,70} because of the shift of stress to those still mobile joints^{12,20,52,53,70,77}.

The most successful long-term results⁵⁹ after an operative procedure for correction of valgus deformity of the hindfoot have been documented after the calcaneal lengthening osteotomy described by Evans²⁵. Evans reported that this procedure is useful for the treatment of calcaneovalgus and planovalgus deformities due to multiple etiologies. He believed that the procedure was contraindicated for valgus deformity of the hindfoot in children who had cerebral palsy or myelomeningocele, although data were not provided to support this conclusion. He theorized that the muscle imbalance in conditions associated with spasticity and the osteopenia associated with myelomeningocele would lead to poor results. In point of fact, these same concerns exist with any procedure, including arthrodesis, that is performed in these children.

I studied the short-term results of correction of severe, intractably symptomatic valgus deformities of the hindfoot in children with use of a modification of the calcaneal lengthening osteotomy described by Evans²⁵. The versatility of the procedure was tested insofar as the deformities in these feet represented a wide range of underlying etiologies: twenty-four of the thirty-one feet were in patients who had cerebral palsy or myelomeningocele. This procedure was chosen because of its documented ability to correct the abnormal anatomy resulting from the deformity while preserving motion at the subtalar joint^{2,4,25,59}.

Materials and Methods

Thirty-one severe, symptomatic valgus deformities of the hindfoot in twenty consecutive patients were corrected with a modification of the calcaneal lengthening osteotomy described by Evans²⁵ (Table I). The procedures were performed at Children's Hospital and Medical Center in Seattle between June 1988 and January 1990. The population for this study was non-homogeneous except for the shape of the hindfoot and the disabilities that had resulted. Preoperatively, complete passive correction was possible for only six of the thirty-one valgus deformities of the hindfoot.

The patients had at least one of the following symptoms at the time of presentation: pain on weight-bearing (eighteen feet), a callus (twenty-nine feet), and ulcer-

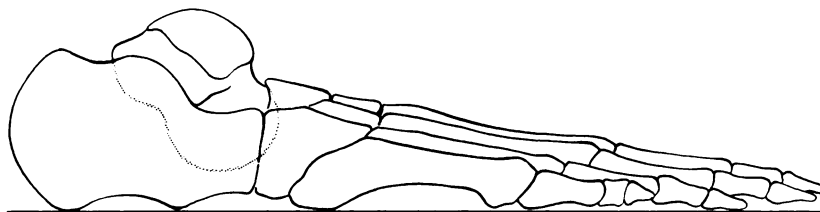


FIG. 2-B

Lateral view of a flatfoot. Plantar flexion of the talus and calcaneus creates a sag of the midfoot.

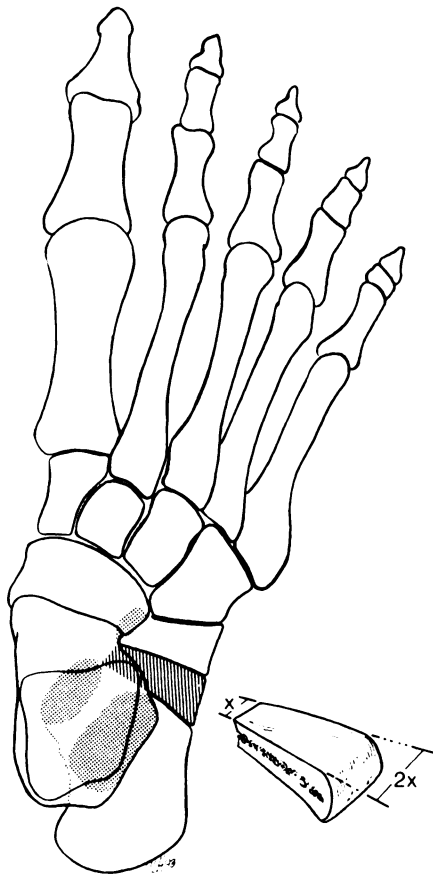


FIG. 2-C

Dorsal view showing correction of all components of the deformity with the trapezoid-shaped graft in place. (The graft is magnified from actual size for detail.)

ation (four feet) under the head of the plantar flexed talus. Intensive efforts to relieve the pain and to eliminate the callus with non-operative treatment, including the use of orthoses and shoe modifications, for a minimum of one year had failed for all of the patients. All of the ulcers healed after local soft-tissue management and strict avoidance of weight-bearing before the operation.

The average age of the eleven boys and nine girls at the time of the operation was ten years and eleven months (range, four years to sixteen years and seven months). The average duration of follow-up was two years and eight months (range, two years to three years

and seven months). Eleven patients had a bilateral procedure, and in ten of them the two sides were operated on concurrently. Nine patients had a unilateral procedure (five on the right and four on the left) (Table I).

Nine patients (sixteen feet) who had myelomeningocele had the calcaneal lengthening osteotomy because a thick, neurotrophic callus or ulcer persisted under the head of the talus despite extensive modifications of the brace. These modifications included the use of Pelite liners and varus molding of the brace for the supple feet and pressure-relief molding of the brace for the rigid feet. There were twelve flatfeet and four skewfeet in this group. A varus derotational osteotomy of the distal part of the tibia was performed concurrently in eight limbs in which valgus alignment of the ankle had created an additional callus or ulceration under the medial malleolus and external tibial torsion was contributing to valgus thrust of the knee and a crouched gait. These eight feet, therefore, had valgus alignment and external rotation at the ankle and subtalar levels. In five feet, an opening-wedge osteotomy of the medial cuneiform was performed concurrently to treat additional deformities between the midfoot and the forefoot.

The calcaneal lengthening osteotomy was used to correct eight flatfeet in six patients who had cerebral palsy. Each patient had severe pain and five had a thick callus under the head of the talus, so that they could not tolerate weight-bearing with or without a custom-molded orthosis. The one patient who did not have a callus had a symptomatic bunion that was treated concurrently with a modification of the McBride procedure¹⁶. All of these patients had lengthening of the short Achilles tendon.

One patient who had a severe, symptomatic, idiopathic skewfoot bilaterally had simultaneous calcaneal lengthening, opening-wedge osteotomy of the medial cuneiform, and lengthening of the Achilles tendon. His normal activities were limited by pain under the head of each plantar flexed talus, large calluses had developed, and his shoes wore out rapidly with less than regular use. The symptoms had not resolved after previous intramuscular recessions of the gastrocnemius muscle.

Calcaneal lengthening was performed at the same time as an arthrodesis of degenerated talonavicular and talocalcaneal joints in one adolescent who had an over-

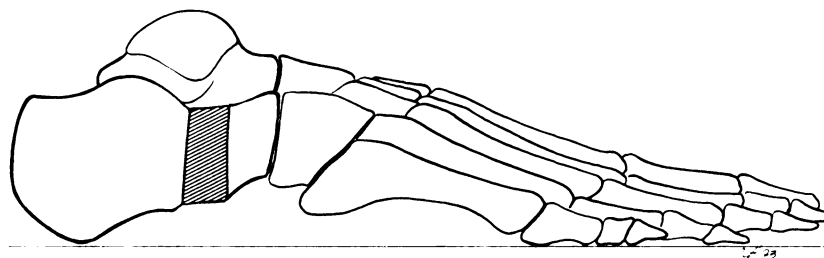


FIG. 2-D

Lateral view showing correction of all components of the deformity with the graft in place.

TABLE I
DATA ON THE PATIENTS

Case	Age (Yrs. + Mos.)	Diagnosis	Side	Previous Operation	Symptoms	Lateral Talo-First Metatarsal Angle* (Degrees)	Lateral Talo- horizontal Angle* (Degrees)	Calcaneal Pitch Angle* (Degrees)	Concurrent Proc.	Type of Bone Graft	Complications	Result
1	9 + 1	Myelomening., flatfoot, valgus ankle, ext. tib. torsion	R	Grice proc.	Callus	41/9	45/21	10/16	Dist. tib. varus- derotat. osteot.	Autogen.	—	Satis.
			L	Grice proc.	Callus	46/20	48/37	0/8	Dist. tib. varus- derotat. osteot.	Autogen.	—	Satis.
2	11 + 1	Myelomening., flatfoot, valgus ankle, ext. tib. torsion	R	—	Callus	5/0	23/24	22/15	Dist. tib. varus- derotat. osteot.	Allogen.	—	Satis.
			L	—	Callus	30/11	39/27	13/15	Dist. tib. varus- derotat. osteot.	Allogen.	—	Satis.
3	15 + 4	Cerebral palsy, flatfoot, short Achilles tendon	R	—	Pain, callus	28/0	38/10	12/22	Talonavic. plic. & tib. post. advance., Achilles tendon length.	Autogen.	Sublux., calc.- cuboid joint	Satis.
4	10 + 5	Myelomening., flatfoot, short Achilles tendon	R	—	Pain, callus	0/0	28/24	14/23	Achilles tendon length.	Allogen.	—	Satis.
5	11 + 2	Myelomening., flatfoot	R	—	Callus	41/0	45/27	7/18	Arthrod., talocal. joint	Allogen.	—	Satis.
6	7 + 0	Cerebral palsy, flatfoot, short Achilles tendon	R	—	Pain, callus	44/0	52/15	3/20	Talonavic. plic. & tib. post. advance., Achilles tendon length., Steinmann pin	Allogen.	Graft slipped, repositioned	Satis.
			L	—	Pain, callus	37/0	46/13	8/20	Talonavic. plic. & tib. post. advance., Achilles tendon length.	Allogen.	Sublux., calc.- cuboid joint	Satis.
7	10 + 10	Myelomening., flatfoot, valgus ankle, ext. tib. torsion	R	—	Callus	22/0	37/21	-3/5	Dist. tib. varus- derotat. osteot.	Allogen.	—	Satis.
			L	—	Callus	31/5	39/21	13/24	Dist. tib. varus- derotat. osteot., talonavic. plic. & tib. post. advance.	Allogen.	—	Satis.
8	16 + 7	Cerebral palsy, flatfoot, short Achilles tendon	R	—	Pain, callus	40/0	44/12	3/20	Achilles tendon length.	Allogen.	—	Satis.
9	13 + 7	Guillain-Barré syn., flatfoot, short Achilles tendon	R	—	Pain, callus	20/0	32/21	15/18	Achilles tendon length.	Allogen.	—	Satis.
			L	—	Pain, callus	23/0	32/24	15/16	Achilles tendon length.	Allogen.	—	Satis.
10	8 + 3	Myelomening., flatfoot, valgus ankle, ext. tib. torsion	R	—	Callus	33/7	38/20	19/30	Dist. tib. varus- derotat. osteot.	Allogen.	—	Satis.
			L	—	Callus	38/12	42/24	13/24	Dist. tib. varus- derotat. osteot.	Allogen.	—	Satis.
11	13 + 1	Skewfoot, short Achilles tendon	R	Gastroc. recess.	Pain, callus	25/0	43/20	9/21	Open.-wedge osteot., med. cuneiform; Achilles tendon length.	Autogen.	—	Satis.
	13 + 7		L	Gastroc. recess.	Pain, callus	23/0	38/21	11/15	Open.-wedge osteot., med. cuneiform; Achilles tendon length.	Autogen.	—	Satis.
12	6 + 2	Cerebral palsy, flatfoot, short Achilles tendon	R	—	Pain, callus	54/10	60/31	6/22	Talonavic. plic. & tib. post. advance., Achilles tendon length.	Autogen.	—	Satis.
			L	—	Pain, callus, ulcer	59/33	64/42	2/23	Talonavic. plic. & tib. post. advance., Achilles tendon length.	Autogen.	Graft slipped, malunion; callus	Un- satis.
13	13 + 6	Cerebral palsy, flatfoot, short Achilles tendon	L	—	Pain, callus	25/2	53/6	2/21	Achilles tendon length.	Allogen.	Sublux., calc.- cuboid joint	Satis.
14	7 + 5	Myelomening., flatfoot	R	—	Pain, callus, ulcer	35/0	40/18	-1/10	Open.-wedge osteot., med. cuneiform; talonavic. plic. & tib. post. advance., Steinmann pin	Allogen.	—	Satis.
			L	—	Pain, callus	30/0	34/18	-3/15	Steinmann pin	Allogen.	—	Satis.

TABLE I (continued)
DATA ON THE PATIENTS

Case	Age (Yrs. + Mos.)	Diagnosis	Side	Previous Operation	Symp- toms	Lateral Talo-First Metatarsal Angle* (Degrees)	Lateral Talo- horizontal Angle* (Degrees)	Calcaneal Pitch Angle* (Degrees)	Concurrent Proc.	Type of Bone Graft	Compli- cations	Result
15	13 + 2	Overcorrected clubfoot, mult. congen. anom.	R	Circumf. release × 2	Pain, callus	33/-6	36/21	11/25	Arthrod., talonav. & talocalc. joints; Steinmann pin	Allogene.	—	Satis.
16	7 + 6	Myelomening., skewfoot, short Achilles tendon	R	—	Callus	38/12	51/27	3/23	Open.-wedge osteot., med. cuneiform; talonav. plic. & tib. post. advance.; Achilles tendon length.; Steinmann pin	Allogene.	—	Satis.
			L	—	Callus, ulcer	52/33	65/43	-7/20	Open.-wedge osteot., med. cuneiform; talonav. plic. & tib. post. advance.; Achilles tendon length.; Steinmann pin	Allogene.	Incomplete correct., callus	Un-satis.
17	4 + 0	Myelomening., skewfoot, short Achilles tendon	R	—	Callus, ulcer	3/0	25/32	14/23	Open.-wedge osteot., med. cuneiform; talonav. plic. & tib. post. advance.; Achilles tendon length.; Steinmann pin	Allogene.	—	Satis.
			L	—	Callus	19/-7	41/19	9/25	Open.-wedge osteot., med. cuneiform; talonav. plic. & tib. post. advance.; Achilles tendon length.; Steinmann pin	Allogene.	—	Satis.
18	15 + 9	Cerebral palsy, flatfoot, bunion, short Achilles tendon	L	—	Pain	19/0	35/21	15/24	McBride proc.; Achilles tendon length.; osteot., 1st metatarsal	Allogene.	—	Satis.
19	5 + 1	Flex. flatfoot, short Achilles tendon	L	Silicone sinus tarsi plug	Pain	35/4	55/29	10/24	Talonavic. plic. & tib. post. advance.; Achilles tendon length.; removal, sinus tarsi plug; Steinmann pin	Allogene.	—	Satis.
20	16 + 6	Talocalc. coal., flatfoot, short Achilles tendon	L	Resect., fat graft	Pain, callus	42/10	53/28	5/20	Talonavic. plic. & tib. post. advance.; Achilles tendon length.; Kidner proc.; Steinmann pin	Allogene.	—	Satis.

*Values are given as preoperative/postoperative.

corrected clubfoot on which multiple operations had been performed. The calcaneal lengthening osteotomy corrected the deformity while helping to preserve the length of the already shortened foot.

One patient, who had a talocalcaneal-tarsal coalition, had calcaneal lengthening to correct severe valgus deformity that had persisted after successful resection and fat-grafting of the coalition. The dorsolateral pain in the foot, characteristic of a coalition, had been relieved by the resection and grafting, but the pain and callus under the head of the talus had persisted.

One of the remaining two patients (one foot) had a severe, flexible flatfoot with a short Achilles tendon, and the other patient (two feet), who had Guillain-Barré syndrome, had paralytic flatfeet. All three feet were

painful, and two had a callus under the plantar flexed head of the talus. The contracted Achilles tendon was lengthened in each of these three feet.

Open z-lengthening of the Achilles tendon was performed in nineteen feet that, after placement of the graft, were noted to lack at least 10 degrees of dorsiflexion of the ankle. Plication of the talonavicular joint with advancement of the tibialis posterior tendon was performed in eight feet on the basis of a non-standardized clinical assessment of stability of the talonavicular joint after placement of the graft. Advancement of the tibialis posterior tendon was specifically added to improve muscle balance in another five feet in children who had cerebral palsy. Longitudinal fixation along the lateral column of the foot with a Steinmann pin was performed

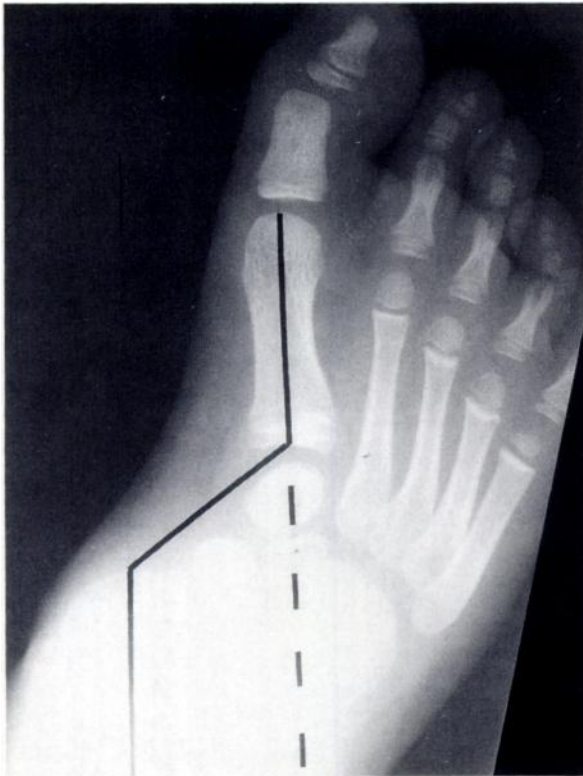


FIG. 3-A

Figs. 3-A and 3-B: A skewfoot.

Fig. 3-A: Anteroposterior radiograph demonstrating the same deformities of the hindfoot as are seen with a flatfoot (Fig. 1-A) but with adduction of the forefoot. There is a so-called normal talo-first metatarsal angle of 0 degrees as the lines representing the axes of these bones are parallel, but the deformities are severe. There is abduction at the talonavicular joint and adduction at the Lisfranc joint. The first metatarsal is laterally translated relative to the talus.

in ten feet because of concern about the stability of the graft or because the calcaneocuboid joint had subluxated on distraction of the site of the osteotomy.

A tricortical iliac-crest allograft was used in twenty-four feet and an autogenous graft, in seven feet. The choice of graft was based on the preference and informed consent of the patient and the parents.

The results were assessed clinically and radiographically. A clinical result was considered satisfactory when the valgus deformity of the hindfoot had been corrected, a longitudinal arch had been created, and the prominence of the talar head had been eliminated (when all were assessed with the patient bearing weight); the pain and callus under the head of the talus had been eradicated; the ulceration had not recurred; and tolerance of the brace and shoes had improved.

Preservation of motion of the subtalar joint was assessed. Any alteration in the patient's needs with regard to bracing was documented. A decrease in the extent of bracing was considered advantageous, but most patients still needed an orthosis because of underlying spasticity or paralysis. The maintenance of correction of the deformity was also assessed, with the acknowledgment that this was a short-term follow-up study.

The choice of which radiographic measurements to use for the assessment of the results was difficult. The purpose of the osteotomy was the same in each patient: to correct the valgus deformity of the hindfoot by dorsiflexion of the talus, inversion of the subtalar complex, and alignment of the talonavicular joint, thereby relieving the weight-bearing pressure under the head of the talus. The anteroposterior and lateral talocalcaneal angles have traditionally been used as the only radiographic measurements for assessment of the operative results in flatfeet. However, these angles do not provide the desired information — that is, the relationship between the bones at the talonavicular joint or the dorsiflexion of the talus from the weight-bearing surface.

Radiographic assessment of the alignment of the talonavicular joint in the frontal plane in young children is unreliable because the normal ossification pattern of the navicular is eccentric from lateral to medial. The anteroposterior talo-first metatarsal angle has traditionally been used as an alternative means to assess the relationship between the forefoot and the hindfoot in young children who have little or no ossification of the navicular^{54,74}. This angle is unreliable because it is meaningful only if there is a single angular deformity between the talus and the first metatarsal. Adduction of the forefoot, as seen in skewfeet and to a lesser extent in certain flatfeet, creates a second angular deformity in that interval in the opposite direction from the first. This artificially improves the anteroposterior talo-first metatarsal angle despite malalignment at the talonavicular joint (Fig. 3-A). This is manifested by lateral translation of the line through the axis of the first metatarsal relative to the line through the axis of the talus or by an intersection of the two lines proximal to the neck of the talus. The lateral talo-first metatarsal angle is less affected by deformity of the forefoot or by correction of a deformity than is the anteroposterior angle.

In consideration of the constraints discussed, I believe that the weight-bearing lateral talo-first metatarsal angle⁵⁴, lateral talohorizontal angle⁷⁴, and calcaneal




FIG. 3-B

Lateral radiograph demonstrating the same deformities of the hindfoot as are seen with a flatfoot (Fig. 1-B) but with plantar flexion of the forefoot on the midfoot, as evidenced by the intersection of the lines of the talus and first metatarsal proximal to the neck of the talus. The skewfoot deformity is indicated by the solid lines, with dorsiflexion at the talonavicular joint and plantar flexion at the Lisfranc joint. The broken line represents the position that the talus should assume after the deformity has been corrected.

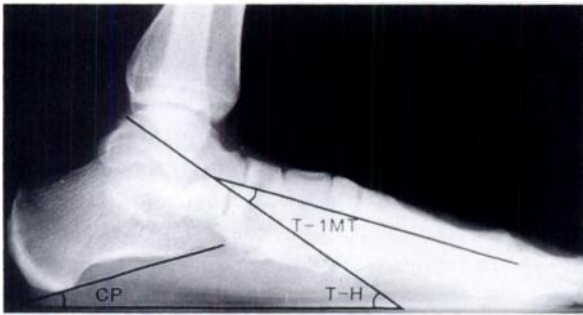


FIG. 4

Weight-bearing lateral radiograph showing the measurements used in the assessment of the results. The calcaneal pitch (CP) is the angle between the plantar aspect of the calcaneus and the floor (a negative value represents plantar flexion beyond the horizontal), the lateral talo-first metatarsal angle (T-1MT) is the angle between the mid-axes of the talus and the first metatarsal (a negative value represents cavus), and the lateral talohorizontal angle (T-H) is the angle between the mid-axis of the talus and the floor.

pitch²⁷ (Fig. 4) best represent the desired information regarding hindfoot relationships. Of the three angles, the calcaneal pitch is the least reliable postoperatively because the landmarks of the cortical margin on the plantar aspect of the calcaneus may change shape when the graft is in place. Nevertheless, it provides another fairly objective way to assess alignment of the hindfoot. None of these three measurements is markedly affected by deformity of the forefoot, and there are generally accepted average values as well as normal ranges for all three measurements^{27,29,33}. In the present study, at least two of these three measurements were in the normal range in the feet with a satisfactory result.

Operative Technique

My technique is a modification of that described by Evans²⁵ with regard to the skin incision, the position and direction of the osteotomy, the shape of the graft, the management of the soft tissues, and the use of internal fixation.

A modified Ollier incision is made over the sinus tarsi, following a Langer skin line and passing approximately one centimeter proximal to the anterior beak of the calcaneus. This incision provides better exposure and is more cosmetically pleasing than the one used by Evans. The sural and superficial branches of the peroneal nerve are protected and retracted when possible.

The inferior extensor retinaculum is released from the superolateral border of the calcaneus. The extensor digitorum brevis and other soft-tissue contents of the sinus tarsi are elevated from the dorsal surface of the anterior aspect of the calcaneus. The peroneus longus and brevis tendons are released from their tendon sheaths enough for them to be retracted freely dorsally and plantarward. One to 1.5 centimeters of the lateral extent of the plantar fascia and the abductor digiti minimi aponeurosis are divided. The calcaneocuboid joint should be identified, but injury to the joint

capsule must be avoided. Dorsal subluxation of the distal calcaneal fragment at the calcaneocuboid joint may occur during distraction of the osteotomy site, and damage to the joint capsule may contribute to this undesired effect.

The middle facet of the subtalar joint (the sustentaculum tali) is identified with a Freer periosteal elevator by probing over the dorsum of the exposed calcaneus. The instrument is moved slowly distally until it slides medially at the point just distal to the middle facet. There is usually a narrow interval between the middle and anterior facets (if the latter is present). A curved Joker elevator is used to replace the Freer elevator through that interval and is placed around the medial aspect of the calcaneus extraperiosteally. A second Joker elevator is placed around the plantar aspect of the calcaneus until the two elevators that are being used as retractors meet. The periosteum is incised in line with the planned osteotomy, starting laterally approximately 1.5 centimeters proximal to the calcaneocuboid joint and aiming for the elevators in the interval between the anterior and middle facets of the subtalar joint (Fig. 2-A). This line is not perpendicular to the lateral border of the foot or parallel with the calcaneocuboid joint but rather is slightly oblique from proximal-lateral to distal-medial. Sturdy, smooth Steinmann pins are placed from lateral to medial both proximal and distal to the planned site of the osteotomy (staying at or plantar to the horizontal mid-axis of the calcaneus). The Steinmann pins act as handles to distract the site of the osteotomy, help to identify completion of the cut of the osteotome through the medial cortex, and allow insertion of the graft without obstruction of the path.

As the center of rotation for correction of the deformity is near the center of the talar head and not at the medial cortex of the calcaneus, this is not a simple opening-wedge osteotomy. It is a lengthening distraction-wedge osteotomy, and it requires a trapezoid-shaped graft. A laminar spreader can be placed in the osteotomy site temporarily and used to determine the size of graft required to reduce the talonavicular joint and the entire subtalar complex to normal anatomical alignment. Intraoperative radiographs with simulation of the standing position can be made at this time or the correction can be assessed clinically. Typically, the graft is ten to twelve millimeters long laterally and four to six millimeters long medially. Overcorrection is highly unlikely. During distraction of the site of the osteotomy, the calcaneocuboid joint must be watched carefully for dorsal subluxation, which is apparent if the distal calcaneal fragment becomes prominent and tents the skin; the subluxation can also be seen on the radiograph. If subluxation occurs, the laminar spreader is removed and the osteotomy is allowed to close. A large, smooth Steinmann pin is inserted longitudinally from the dorsal-distal aspect of the cuboid through the center of the calcaneocuboid joint to the center of the osteot-

omy surface of the distal calcaneal fragment. The site of the osteotomy should again be distracted to check for subluxation of the joint. Occasionally, two pins are needed. The pin or pins can later be advanced through the graft and the proximal calcaneal fragment. The pin can then be bent at the surface of the skin and left long for easy retrieval in the outpatient setting after the bone has healed. Pins are not necessary unless there is subluxation or a concern regarding the stability of the graft.

A trapezoid-shaped tricortical bone graft from the iliac crest is recommended (Fig. 2-C). Allogenic or autogenous bone graft may be used. Only bicortical grafts, which are generally adequate alternatives, can be obtained from children in whom the apophyses have not closed. The cortical edges give the graft immediate structural stability and are aligned axially on the dorsal, lateral, and plantar surfaces. The central cancellous bone provides rapid incorporation. The graft is impacted from lateral to medial in the most plantar portion of the osteotomy. Additional graft may be used depending on the discrepancy between the size of the graft and that of the osteotomized surfaces of the calcaneus. The talonavicular joint will be well aligned and stable in most patients (Figs. 1-C, 1-D, 2-C, and 2-D). I believe that plantar-medial plication of the talonavicular joint capsule with advancement of the tibialis posterior tendon should be performed if, after placement of the appropriate-sized graft, there is mobility at the talonavicular joint in any plane other than along the oblique axis of the subtalar joint. The contribution of these procedures to the end result, however, has not been demonstrated clearly. In order to improve muscle balance, these two additional procedures are performed along with z-lengthening of the peroneal tendons in the feet of children who have cerebral palsy. Z-lengthening of the peroneal tendons is also performed, in any patient, if those tendons markedly resist distraction of the site of the osteotomy. The Achilles tendon is lengthened if, after placement of the graft, the ankle lacks at least 10 degrees of dorsiflexion when assessed with the knee extended.

Any additional or ancillary procedures on the foot and ankle that are necessary should be performed after the graft has been placed in the calcaneal osteotomy site. Adjacent deformities become more apparent after correction of the deformity of the hindfoot. A plantar-medial opening-wedge osteotomy of the medial cuneiform can be used to correct the deformity of the forefoot in skewfeet. Most longstanding flatfeet have rigid supination of the forefoot, which is a separate deformity and necessitates individual attention. A plantar-medial closing-wedge osteotomy of the medial cuneiform gives a satisfactory result in many of these feet. Children who have myelomeningocele or poliomyelitis frequently have external tibial torsion and valgus deformity of the ankle in addition to the multiplanar deformity of the foot. The osteotomy described by Evans²⁵ corrects

external rotation and valgus deformity in the subtalar complex to a finite, but unpredictable, degree. A varus derotational osteotomy of the distal part of the tibia can correct the tibial deformities. The degree of rotation and the amount of bone removed are adjustable, so accurate final correction of the malalignment of the lower limb is possible. The varus derotational osteotomy of the distal part of the tibia should, therefore, be performed second under the same or subsequent anesthesia.

Non-weight-bearing with the leg in a below-the-knee cast is maintained for eight weeks. The cast is changed at six weeks to allow radiographic assessment of healing and to permit removal of the pin. An above-the-knee cast is used if it is anticipated that compliance with non-weight-bearing will be a problem. New brace molds are made at six weeks for children who have an underlying neuromuscular disorder.

Results

All of the patients were available for clinical and radiographic evaluation at the time that the data were collected (Table I). Twenty-nine of the thirty-one feet had a satisfactory clinical result: pain and callusing under the head of the plantar flexed talus had been eradicated, the ulceration had not recurred, the valgus deformity of the hindfoot had been corrected, a longitudinal arch had been created, and the prominence of the talar head had been eliminated when assessed with the patient bearing weight. The unsatisfactory result in the remaining two feet was the result of a technical error and extreme deformity in one foot and of extreme deformity alone in the other foot. In the foot that had a technical error, the graft slipped in the immediate post-operative period and the slip was not recognized until the osteotomy had healed in malalignment. The over-all alignment of both of the feet that had an unsatisfactory result was markedly improved, but a small callus persisted under the talar heads. The patient who had the technical error and extreme deformity no longer had pain, and the preoperative ulceration had not recurred in the other patient at the time of the most recent follow-up examination. Both patients and their parents were pleased with the results and considered the operations to have been successful.

Use of the brace was discontinued for eight of the twenty-five feet that had been braced. Paralysis or spasticity necessitated continued use of the brace for the remaining seventeen feet.

Clinical evaluation of subtalar motion is difficult to quantitate and has never been correlated with radiographic findings⁴⁰, to my knowledge. Therefore, no attempt was made to legitimize the assessment with unverifiable numbers. There was clear preservation of motion of the subtalar joint in all twenty-seven feet that had not had a simultaneous or previous subtalar arthrodesis. I believe that the total arc of motion remained unchanged after the osteotomy, but the posi-

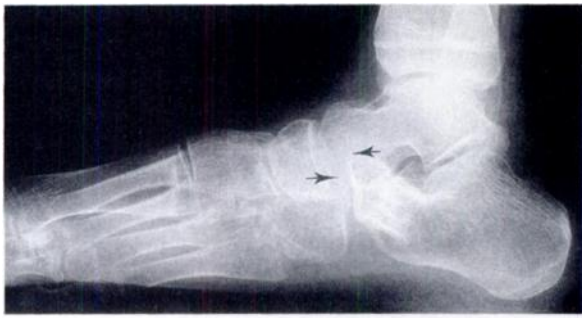

FIG. 5

Lateral radiograph showing dorsal subluxation of the distal calcaneal fragment at the calcaneocuboid joint (arrows), which occurred during placement of the graft.

tion of the arc was shifted from valgus to neutral.

Twenty-nine of the thirty-one feet had a satisfactory radiographic result in that at least two of the three radiographic measurements were within the normal ranges. The lateral talo-first metatarsal angle was corrected from an average of 31 degrees (range, 0 to 59 degrees) of sag of the midfoot preoperatively to 5 degrees (range, -7 to 33 degrees) postoperatively. The normal average value is 5 degrees (two-standard-deviation range, -7 to 20 degrees)^{71,74}. The lateral talohorizontal angle was corrected from an average of 43 degrees (range, 23 to 65 degrees) to 23 degrees (range, 6 to 43 degrees). The normal average value is 27 degrees (two-standard-deviation range, 15 to 37 degrees)⁷³. The calcaneal pitch was corrected from an average of 8 degrees (range, -7 to 22 degrees) to 20 degrees (range, 5 to 30 degrees). The normal average value is 25 degrees (two-standard-deviation range, 15 to 30 degrees)^{77,71,74}. In two feet, the postoperative lateral talo-first metatarsal and talohorizontal angles were not in the normal range. These were the same two feet that had an unsatisfactory clinical result. In three other feet, only the calcaneal pitch was not in the normal range; all three of these feet had a satisfactory clinical result.

One additional graft slipped, and this was recognized radiographically the following day. The graft was repositioned and pinned.

In some feet, the distal fragment of the calcaneus at the calcaneocuboid joint tends to subluxate dorsally during placement of the graft. This occurred in three feet before it was recognized as a problem (Fig. 5). The clinical and radiographic results in these feet were otherwise satisfactory, and no disability has yet been associated with this finding. Later in the series, subluxation was controlled with longitudinal placement of a Steinmann pin across the joint before insertion of the graft in susceptible feet.

All bone grafts united with the calcaneus within two months, and there was no detectable difference attributable to the source of the graft. Complete incorporation and remodeling occurred within one year. Preoperatively, there had been concern that osteopenia in

the feet with a neuromuscular deformity might compromise the result, but this was not a problem, even in the four-year-old child who had myelomeningocele.

The duration of the calcaneal lengthening procedure was difficult to ascertain because additional procedures were frequently done during the same period of anesthesia. Blood loss was minimum because a tourniquet was used. There were no infections or other soft-tissue complications; no neuromas were identified.

There was no deterioration of the clinical or radiographic result in any foot at the time of the latest follow-up examination. This suggests that the procedure did not interfere with continued calcaneal growth, as retardation of growth of the lateral column should lead to recurrence of deformity. Long-term follow-up is necessary to assess maintenance of correction of the deformity.

Discussion

Many different operations have been proposed for the correction of flatfoot deformity^{10,11,13,16,21,22,25,28,33,36,39,41,42,44,47,55,56,58,62,64,69,72,78}, but the indications for these procedures have not been clearly defined. Most procedures have had good short-term but poor long-term results and have been abandoned^{11,16,28,33,36,41,44,47,55,58,62,64,69,72,78}. The most common procedures used today are modifications of the limited mid-tarsal arthrodesis described by Hoke^{10,13,21,36,39,56}. However, unsatisfactory long-term results with those procedures were reported by Butte⁹ in sixty-eight (49 per cent) of 138 feet, by Crego and Ford¹⁴ in seven of nine feet, and by Seymour⁷ in sixteen (50 per cent) of thirty-two feet. The poor results were attributed to the persistence or recurrence of pain and deformity and to the development of degenerative osteoarthritis at the talonavicular and subtalar joints. The authors of these studies recommended triple arthrodesis for severe flatfoot deformities, which, they stated, are not correctable with modifications of the limited arthrodesis.

Subtalar and triple arthrodeses have been the most commonly used operative procedures for neuromuscular and other valgus deformities of the hindfoot, including skewfoot. Numerous short-term follow-up studies have demonstrated reasonably good results based on non-rigid criteria^{7,8,17,19,20,23,26,29,32,37,38,43,49,51,60,61,73,75,76}. A comparison of the results of the present study with the results of these studies is difficult for several reasons. The success of any of the procedures should be judged on the basis of the relief of symptoms, the adequacy and maintenance of correction of the deformity, the restoration of function, and a favorable long-term prognosis. Surprisingly, very few of the short-term studies included a critical assessment of any of these criteria. Instead, the authors focused on the rate of fusion. Many authors described modifications of the original techniques of arthrodesis and highlighted the superiority of these modifications in achieving a solid fusion^{7,8,17,31,32,37,38,43,57,60,76}. Planovalgus deformity of the foot is frequently stated as the indication for the operation without consideration

of the severity of the deformity or the exact symptoms present. In most studies, the result was judged to be satisfactory if the foot looked better than it did preoperatively. Some authors have stated that subtalar arthrodesis is not a corrective procedure but simply a stabilizing one^{26,37,65}. In many of these short-term studies, the lateral talocalcaneal angle alone was used to quantitate radiographic correction of the deformity. Although the so-called normal range for this measurement was achieved in most patients, the feet were still flat. This is evidenced by the low calcaneal pitch, persistent plantar flexion of the talus, and sag of the lateral talo-first metatarsal line seen on the radiographs of the feet that had a so-called satisfactory result in many of the published reports^{7,17,29,32,37,49,60,73}.

Reports of long-term follow-up studies of subtalar and triple arthrodeses have consistently described technical difficulty, undercorrection, overcorrection, non-union, recurrent deformity, avascular necrosis of the talus, instability of the ankle, and the development of substantial degenerative osteoarthritis in the ankle and other adjacent joints of the foot^{1,3,5,6,15,18,57,63,65,66,68,70}. Ross and Lyne⁶³ reported an unsatisfactory long-term result in seventy-two (64 per cent) of 113 feet that had a subtalar arthrodesis; Scott et al.⁶⁵, in thirty-eight (61 per cent) of sixty-two feet that had a subtalar arthrodesis; and Angus and Cowell³, in sixty (75 per cent) of eighty feet that had a triple arthrodesis. Degenerative osteoarthritis in joints adjacent to a triple arthrodesis was reported in twenty-one (58 per cent) of thirty-six ankles and in eighteen (50 per cent) of thirty-six naviculocuneiform joints by Southwell and Sherman⁷⁰ and in thirty-one (39 per cent) of eighty ankles and in forty-three (54 per cent) of eighty midfoot joints by Angus and Cowell³. Triple arthrodesis also shortens and slows the growth of the foot in a young child. The poorest results reported after a subtalar or triple arthrodesis were in patients who had myelomeningocele.

Evans developed the calcaneal lengthening osteotomy on the basis of his knowledge, as early as 1959, that triple arthrodesis was undesirable in the foot of a child²⁵. He believed that one element of residual clubfoot (varus) deformity in older children was a relative overgrowth of the lateral column of the foot. On this basis, he developed a procedure for shortening of the lateral column through arthrodesis of the calcaneocuboid joint and, in 1961, he reported the successful correction of the deformity with this operation²⁴. Removal of too much bone in two feet resulted in the creation of valgus deformities, which he called calcaneovalgus deformities. On the basis of differences in the relative lengths of the medial and lateral columns of the foot, Evans reasoned that varus and valgus are opposite deformities. He believed that the only point at which to shorten the lateral column was the calcaneocuboid joint but that the best site at which to lengthen the lateral column was the anterior portion of the calcaneus approximately 1.5

centimeters proximal to, and parallel with, the calcaneocuboid joint. In 1975, he noted the importance of preserving that joint if possible when he reported on lengthening of the lateral column for correction of severe calcaneovalgus deformity²⁵. The relative obscurity of this procedure may be accounted for by the brevity of the description of the operative technique²⁵.

Armstrong and Carruthers⁴ recommended the procedure described by Evans²⁵ and confirmed that its advantages were correction of valgus deformity of the hindfoot without the need for an arthrodesis, preservation of some subtalar motion, versatility for feet with pronation and abduction deformities of different etiologies, and simplicity of execution. Phillips⁵⁹ reported on a follow-up of the patients originally reported on by Evans²⁴. At seven to twenty years (average, thirteen years), seventeen of the twenty-three feet had a good or very good result when assessed with strict criteria that included relief of symptoms (pain); clinical appearance; function; mobility of the joints; and radiographic evidence of correction of the deformity (in two planes), maintenance of correction, and no or only mild degenerative osteoarthritis. To my knowledge, that study demonstrated the best long-term results of any procedure used to correct flatfeet. Anderson and Fowler² also reported very good results with this procedure in nine feet that were followed for an average of six and one-half years. They reconfirmed the ability of this procedure to correct all components of the deformity and recommended that it be performed between the ages of six and ten years in appropriate individuals. Evans²⁵ recommended correction between the ages of eight and twelve years or earlier if necessary. He stated that the operation could be repeated if full correction was not possible on the first attempt. He also stated that overcorrection was possible in certain feet.

The mechanism by which calcaneal lengthening corrects valgus deformity of the hindfoot is unknown, but it is suggested by my observations on the effects of lengthening without release of the lateral plantar fascia and the abductor digiti minimi aponeurosis. Tethering by these plantar-lateral soft tissues creates an undesired cavus deformity between the two fragments of the calcaneus, with its apex at the site of the osteotomy, as well as dorsal subluxation of the distal fragment of the calcaneus. This local windlass effect can be decreased with release of the soft tissues involved. The implication seems to be that the desired elevation of the longitudinal arch and the correction of the valgus deformity of the hindfoot by calcaneal lengthening is due to the windlass effect of the central plantar fascia. The distal aspect of the calcaneus, along with the cuboid, navicular, and spring ligament, are pushed distally. The central plantar fascia, being of fixed length, resists straight distal distraction at the site of the osteotomy. The arch elevates and the subtalar complex inverts in a manner suggestive of the Jack toe-raising test³⁹. In the Jack toe-

raising test, the plantar fascia is effectively shortened relative to the length of the bones of the foot as the great toe is dorsiflexed. The calcaneus is pulled toward the head of the first metatarsal, and the arch elevates. With the Evans procedure²⁵, the bones of the foot are lengthened relative to the length of the plantar fascia with the same structural effect.

Attention to the details of the procedure, as documented in the present study, should help to ensure a successful outcome even if the surgeon uses the procedure only occasionally. Success is also based on the preoperative and intraoperative identification of all sites of adjacent deformity and their correction. Many of the unsatisfactory results in series on arthrodeses of the hindfoot were in patients with poliomyelitis or myelomeningocele in whom valgus deformity of the ankle was not fully appreciated preoperatively^{1,31,49,51,60,61,63,65,68}. Concurrent or staged osteotomies of the distal aspect of the tibia and the mid-tarsal bones can correct adjacent deformities without compromising the correction of the valgus deformity of the hindfoot achieved with the Evans procedure²⁵.

If there is already degenerative osteoarthritis, the osteotomy can be used in conjunction with arthrodesis to enable better correction of the deformity while preserving the length of the foot.

The results of the present study demonstrate that calcaneal lengthening provides good clinical and radiographic correction of all components of even severe valgus deformity of the hindfoot (regardless of etiology or rigidity) in children as young as four years old. It reliably relieves symptoms, restores function of the subtalar complex, and theoretically protects the ankle and mid-tarsal joints from early degenerative osteoarthritis. If painful degenerative osteoarthritis develops later, it will probably be within the subtalar complex — that is, the site of the original deformity. Arthrodesis of those joints later will be relatively easy because the deformity will already have been corrected. The time between procedures can be considered a period of stress avoidance for the ankle and mid-tarsal joints. Calcaneal lengthening, like subtalar and triple arthrodeses, may not be the final procedure on any foot, but it leaves more options open for the future.

References

1. Adelaar, R. S.; Dannelly, E. A.; Meunier, P. A.; Stelling, F. H.; Goldner, J. L.; and Colvard, D. F.: A long term study of triple arthrodesis in children. *Orthop. Clin. North America*, 7: 895-908, 1976.
2. Anderson, A. F., and Fowler, S. B.: Anterior calcaneal osteotomy for symptomatic juvenile pes planus. *Foot and Ankle*, 4: 274-283, 1984.
3. Angus, P. D., and Cowell, H. R.: Triple arthrodesis. A critical long-term review. *J. Bone and Joint Surg.*, 68-B(2): 260-265, 1986.
4. Armstrong, G., and Carruthers, C. C.: Evans elongation of lateral column of the foot for valgus deformity. In Proceedings of the Canadian Orthopaedic Association. *J. Bone and Joint Surg.*, 57-B(4): 530, 1975.
5. Baker, L. D., and Dodelin, R. A.: Extra-articular arthrodesis of the subtalar joint (Grice procedure). Results in seventeen patients with cerebral palsy. *J. Am. Med. Assn.*, 168: 1005-1008, 1958.
6. Baker, L. D., and Hill, L. M.: Foot alignment in the cerebral palsy patient. *J. Bone and Joint Surg.*, 46-A: 1-15, Jan. 1964.
7. Barrasso, J. A.; Wile, P. B.; and Gage, J. R.: Extraarticular subtalar arthrodesis with internal fixation. *J. Pediat. Orthop.*, 4: 555-559, 1984.
8. Brown, A.: A simple method of fusion of the subtalar joint in children. *J. Bone and Joint Surg.*, 50-B(2): 369-371, 1968.
9. Butte, F. L.: Navicular-cuneiform arthrodesis for flat-foot. An end-result study. *J. Bone and Joint Surg.*, 19: 496-502, April 1937.
10. Caldwell, G. D.: Surgical correction of relaxed flat foot by the Durham flatfoot plasty. *Clin. Orthop.*, 2: 221-226, 1953.
11. Chambers, E. F. S.: An operation for the correction of flexible flat feet of adolescents. *Western J. Surg., Obstet. and Gynec.*, 54: 77-86, 1946.
12. Close, J. R.; Inman, V. T.; Poor, P. M.; and Todd, F. N.: The function of the subtalar joint. *Clin. Orthop.*, 50: 159-179, 1967.
13. Coleman, S. S.: Severe, flexible planovalgus foot (flatfoot). In *Complex Foot Deformities in Children*, pp. 193-222. Philadelphia, Lea and Febiger, 1983.
14. Crego, C. H., Jr., and Ford, L. T.: An end-result study of various operative procedures for correcting flat feet in children. *J. Bone and Joint Surg.*, 34-A: 183-195, Jan. 1952.
15. Crego, C. H., Jr., and McCarroll, H. R.: Recurrent deformities in stabilized paralytic feet. A report of 1100 consecutive stabilizations in poliomyelitis. *J. Bone and Joint Surg.*, 20: 609-620, July 1938.
16. Davy, R.: On excision of the scaphoid bone for the relief of confirmed flat-foot. *Lancet*, 1: 675-677, 1889.
17. Dennyson, W. G., and Fulford, G. E.: Subtalar arthrodesis by cancellous grafts and metallic internal fixation. *J. Bone and Joint Surg.*, 58-B(4): 507-510, 1976.
18. Drew, A. J.: The late results of arthrodesis of the foot. *J. Bone and Joint Surg.*, 33-B(4): 496-502, 1951.
19. Drvaric, D. M.; Schmitt, E. W.; and Nakano, J. M.: The Grice extra-articular subtalar arthrodesis in the treatment of spastic hindfoot valgus deformity. *Devel. Med. and Child Neurol.*, 31: 665-669, 1989.
20. Duncan, J. W., and Lovell, W. W.: Hoke triple arthrodesis. *J. Bone and Joint Surg.*, 60-A: 795-798, Sept. 1978.
21. Duncan, J. W., and Lovell, W. W.: Modified Hoke-Miller flatfoot procedure. *Clin. Orthop.*, 181: 24-27, 1983.
22. Dwyer, F. C.: Osteotomy of the calcaneum for pes cavus. *J. Bone and Joint Surg.*, 41-B(1): 80-86, 1959.
23. Engstrom, A.; Erikson, V.; and Hjelmstedt, A.: The results of extra-articular subtalar arthrodesis according to the Green-Grice method in cerebral palsy. *Acta Orthop. Scandinavica*, 45: 945-951, 1974.
24. Evans, D.: Relapsed club foot. *J. Bone and Joint Surg.*, 43-B(4): 722-733, 1961.
25. Evans, D.: Calcaneo-valgus deformity. *J. Bone and Joint Surg.*, 57-B(3): 270-278, 1975.
26. Gallien, R.; Morin, F.; and Marquis, F.: Subtalar arthrodesis in children. *J. Pediat. Orthop.*, 9: 59-63, 1989.
27. Gamble, F. O., and Yale, I.: *Clinical Foot Roentgenology*, p. 153. Baltimore, Williams and Wilkins, 1966.
28. Golding-Bird, C. H.: Operations on the tarsus in confirmed flat-foot. *Lancet*, 1: 677, 1889.

29. **Grice, D. S.:** An extra-articular arthrodesis of the subastragalar joint for correction of paralytic flat feet in children. *J. Bone and Joint Surg.*, 34-A: 927-940, Oct. 1952.
30. **Grice, D. S.:** Further experience with extra-articular arthrodesis of the subtalar joint. *J. Bone and Joint Surg.*, 37-A: 246-259, April 1955.
31. **Gross, R. H.:** A clinical study of the Batchelor subtalar arthrodesis. *J. Bone and Joint Surg.*, 58-A: 343-349, April 1976.
32. **Guttman, G.:** Modification of the Grice-Green subtalar arthrodesis in children. *J. Pediat. Orthop.*, 1: 219-221, 1981.
33. **Haraldsson, S.:** Pes plano-valgus staticus juvenilis and its operative treatment. *Acta Orthop. Scandinavica*, 35: 234-256, 1965.
34. **Harris, R. I., and Beath, T.:** *Army Foot Survey. An Investigation of Foot Ailments in Canadian Soldiers*, vol. 1. Ottawa, National Research Council of Canada, 1947.
35. **Harris, R. I., and Beath, T.:** Hypermobile flat-foot with short tendo achillis. *J. Bone and Joint Surg.*, 30-A: 116-138, Jan. 1948.
36. **Hoke, M.:** An operation for the correction of extremely relaxed flatfeet. *J. Bone and Joint Surg.*, 13: 773-783, Oct. 1931.
37. **Hsu, L. C. S.; Jaffray, D.; and Leong, J. C. Y.:** The Batchelor-Grice extra-articular subtalar arthrodesis. *J. Bone and Joint Surg.*, 68-B(1): 125-127, 1986.
38. **Hunt, J. C., and Brooks, A. L.:** Subtalar extra-articular arthrodesis for correction of paralytic valgus deformity of the foot. Evaluation of forty-four procedures with particular reference to associated tendon transference. *J. Bone and Joint Surg.*, 47-A: 1310-1314, Oct. 1965.
39. **Jack, E. A.:** Naviculo-cuneiform fusion in the treatment of flat foot. *J. Bone and Joint Surg.*, 35-B(1): 75-82, 1953.
40. **Jahss, M. H.:** The subtalar complex. In *Disorders of the Foot and Ankle. Medical and Surgical Management*, edited by M. H. Jahss. Ed. 2, p. 1335. Philadelphia, W. B. Saunders, 1991.
41. **Jones, B. S.:** Flat foot. A preliminary report of an operation for severe cases. *J. Bone and Joint Surg.*, 57-B(3): 279-282, 1975.
42. **Koutsogiannis, E.:** Treatment of mobile flat foot by displacement osteotomy of the calcaneus. *J. Bone and Joint Surg.*, 53-B(1): 96-100, 1971.
43. **Lancaster, S. J., and Pohl, R. O.:** Green-Grice extraarticular subtalar arthrodesis: results using a fibular graft. *J. Pediat. Orthop.*, 7: 29-33, 1987.
44. **Lanham, R. H., Jr.:** Indications and complications of arthroereisis in hypermobile flatfoot. *J. Am. Podiat. Assn.*, 69: 178-185, 1979.
45. **Legg, A. T.:** The treatment of congenital flat-foot by tendon transplantation. *Am. J. Orthop. Surg.*, 10: 584-586, 1913.
46. **LeLievre, J.:** Current concepts and correction in the valgus foot. *Clin. Orthop.*, 70: 43-55, 1970.
47. **Lowman, C. L.:** An operative method for correction of certain forms of flatfoot. *J. Am. Med. Assn.*, 81: 1500-1502, 1923.
48. **McBride, E. D.:** A conservative operation for bunions. *J. Bone and Joint Surg.*, 10: 735-739, Oct. 1928.
49. **McCall, R. E.; Lillich, J. S.; Harris, J. R.; and Johnston, F. A.:** The Grice extraarticular subtalar arthrodesis: a clinical review. *J. Pediat. Orthop.*, 5: 442-445, 1985.
50. **McCormick, D. W., and Blount, W. P.:** Metatarsus adductovarus. "Skewfoot." *J. Am. Med. Assn.*, 141: 449-453, 1949.
51. **Mallon, W. J., and Nunley, J. A.:** The Grice procedure. Extra-articular subtalar arthrodesis. *Orthop. Clin. North America*, 20: 649-654, 1989.
52. **Mann, R. A.:** Surgical implications of biomechanics of the foot and ankle. *Clin. Orthop.*, 146: 111-118, 1980.
53. **Manter, J. T.:** Movements of the subtalar and transverse tarsal joints. *Anat. Rec.*, 80: 397-410, 1941.
54. **Meary, R.:** Symposium. Le pied creux essential. *Rev. chir. orthop.*, 53: 389-467, 1967.
55. **Miller, G. R.:** The operative treatment of hypermobile flatfeet in the young child. *Clin. Orthop.*, 122: 95-101, 1977.
56. **Miller, O. L.:** A plastic flat foot operation. *J. Bone and Joint Surg.*, 9: 84-91, Jan. 1927.
57. **Olney, B. W., and Menelaus, M. B.:** Triple arthrodesis of the foot in spina bifida patients. *J. Bone and Joint Surg.*, 70-B(2): 234-235, 1988.
58. **Phelps, A. M.:** The etiology, pathology, and treatment of flat-foot. *Post-Grad.*, 7: 104-108, 1892.
59. **Phillips, G. E.:** A review of elongation of os calcis for flat feet. *J. Bone and Joint Surg.*, 65-B(1): 15-18, 1983.
60. **Pirani, S. P.; Tredwell, S. J.; and Beauchamp, R. D.:** Extraarticular subtalar arthrodesis: the dowel method. *J. Pediat. Orthop.*, 10: 244-247, 1990.
61. **Pollock, J. H., and Carrell, B.:** Subtalar extra-articular arthrodesis in the treatment of paralytic valgus deformities. A review of 112 procedures in 100 patients. *J. Bone and Joint Surg.*, 46-A: 533-541, April 1964.
62. **Roberts, P. W.:** An operation for valgus feet. *J. Am. Med. Assn.*, 77: 1571-1572, 1921.
63. **Ross, P. M., and Lyne, E. D.:** The Grice procedure: indications and evaluation of long-term results. *Clin. Orthop.*, 153: 194-200, 1980.
64. **Ryerson, E. W.:** Tendon transplantation in flat-foot. *Am. J. Orthop. Surg.*, 7: 505-507, 1910.
65. **Scott, S. M.; Janes, P. C.; and Stevens, P. M.:** Grice subtalar arthrodesis followed to skeletal maturity. *J. Pediat. Orthop.*, 8: 176-183, 1988.
66. **Seitz, D. G., and Carpenter, E. B.:** Triple arthrodesis in children: a ten-year review. *Southern Med. J.*, 67: 1420-1424, 1974.
67. **Seymour, N.:** The late results of naviculo-cuneiform fusion. *J. Bone and Joint Surg.*, 49-B(3): 558-559, 1967.
68. **Smith, J. B., and Westin, G. W.:** Subtalar extra-articular arthrodesis. *J. Bone and Joint Surg.*, 50-A: 1027-1035, July 1968.
69. **Smith, S. D., and Millar, E. A.:** Arthrorisis by means of a subtalar polyethylene peg implant for correction of hindfoot pronation in children. *Clin. Orthop.*, 181: 15-23, 1983.
70. **Southwell, R. B., and Sherman, F. C.:** Triple arthrodesis: a long-term study with force plate analysis. *Foot and Ankle*, 2: 15-24, 1981.
71. **Steel, M. W., III; Johnson, K. A.; DeWitz, M. A.; and Ilstrup, D. M.:** Radiographic measurements of the normal adult foot. *Foot and Ankle*, 1: 151-158, 1980.
72. **Stokes, W.:** Astragaloid osteotomy in the treatment of flat-foot. *Trans. Acad. Med. Ireland*, 3: 141-147, 1885.
73. **Tohen, A.; Carmona, J.; Chow, L.; and Rosas, J.:** Extra-articular subtalar arthrodesis. A review of 286 operations. *J. Bone and Joint Surg.*, 51-B(1): 45-52, 1969.
74. **Vanderwilde, R.; Staheli, L. T.; Chew, D. E.; and Malagon, V.:** Measurements on radiographs of the foot in normal infants and children. *J. Bone and Joint Surg.*, 70-A: 407-415, March 1988.
75. **Westin, G. W., and Hall, C. B.:** Subtalar extra-articular arthrodesis. A preliminary report of a method of stabilizing feet in children. *J. Bone and Joint Surg.*, 39-A: 501-512, June 1957.
76. **Williams, P. F., and Menelaus, M. B.:** Triple arthrodesis by inlay grafting — a method suitable for the undeformed or valgus foot. *J. Bone and Joint Surg.*, 59-B(3): 333-336, 1977.
77. **Wright, D. G.; Desai, S. M.; and Henderson, W. H.:** Action of the subtalar and ankle-joint complex during the stance phase of walking. *J. Bone and Joint Surg.*, 46-A: 361-382, 464, March 1964.
78. **Young, C. S.:** Operative treatment of pes planus. *Surg., Gynec. and Obstet.*, 68: 1099-1101, 1939.