



Helix wire osteosynthesis of proximal humerus fractures : Unacceptably high rate of failure

Suhab Ali KHAN

From Glostrup Hospital, Copenhagen, Denmark

The aim of this study was to assess the success rate of osteosynthesis of proximal humerus fractures with titanium helix wires. We retrospectively reviewed the charts of 37 patients who underwent fixation with a helix wire after fracture of the proximal humerus from June 2003 till June 2006. Three patients were excluded because of insufficient details of admission and follow-up. Median age was 64 years (range : 22 to 89). Fractures were classified according to Neer's classification : there were two 3-fragment fractures, thirty 2-fragment fractures and two undisplaced fractures. Internal fixation was performed on average 2.5 days after trauma. During operation either one (18) or two (16) helix wires were used depending on fracture stability. Postoperative immobilisation included approximately 2 weeks in a fixed arm sling and 2 weeks in a collar and cuff. First follow-up was at an average of 2.3 weeks and final follow-up at 14.8 weeks. Follow-up included both radiological and clinical assessment. Already at first follow-up 7 (20%) fractures were displaced, and further surgery was indicated. At final follow-up 9 more fractures were labelled as failures. There was an overall failure rate of 47%. Although helix wire osteosynthesis is a less invasive surgical technique, a failure rate of 47% overshadows the effectiveness of this method. We do not recommend this method for treatment of proximal humeral fractures.

Keywords : proximal humerus fracture ; helix wire ; radiological healing ; secondary displacement ; non-union.

INTRODUCTION

The treatment of fractures of the proximal humerus ranges from conservative treatment to primary hemiarthroplasty. Among the surgical options, a less invasive technique is always preferable, especially in the elderly patients. One of the less invasive methods is titanium Helix Wire osteosynthesis. The Helix Wire is produced by Implantat Technologie Systeme GmbH (Graz, Austria) and consists of a titanium helical spring. The operation technique is relatively simple. A 4-5 cm long vertical incision is made at the anterolateral aspect of the upper-arm, at the junction of the proximal one-third and the distal two-thirds of the proximal humerus. After blunt dissection through the soft tissue, an entry point is made through the cortex into the medullary canal. A helix wire is then introduced and advanced proximally into the

■ Suhab Ali Khan, MBBS (Pesh.), Resident orthopaedic surgeon.

Department of Orthopaedics, Glostrup Hospital, Copenhagen, Denmark.

Correspondence : Suhab Ali Khan, Resident orthopaedic surgeon, Department of Orthopaedics, Glostrup Hospital, Nordre Ringvej 57, 2600 Glostrup, Denmark.

E-mail : suhabali@gmail.com

© 2008, Acta Orthopædica Belgica.

medullary canal by rotating the implant until the proximal end of the helix wire engages the humeral head. The distal end of the wire is cut close to the bone, leaving only 3-4 mm of wire protruding through the cortex. The fixation achieved is semi-rigid. There are three points of fixation : the lateral cortex of the humerus distally, the medial cortex in the middle and the trabecular bone in the humeral head proximally. Depending upon the stability of the fracture, either one or two helix wires can be used. The method has certain benefits, which include : minimally invasive surgery, minimal stress for the patient, removal of implant is not necessary and there is no migration of the implant as compared to Kirschner wires, which are known to migrate. Other benefits include : simple approach avoiding injury to the axillary nerve (6), minimal damage to surrounding soft tissue, which minimises the risk of humeral head necrosis (2).

A theoretical flaw with this technique lies in the flexible nature of the helix wire. An experiment done on the dynamic titanium Helix Wire (1) showed that application of a load of 50 N, the approximate weight of a human arm, can displace a single coil up to 380 μm . Dynamic micro-displacements of this magnitude help the healing process. The critical value for the examined helix wire was 130 N. When the arm is moved, the inertial load doubles, and the total load acting on the implant may easily approach the critical value, which can result in macro-displacements of the fracture fragments, and may also cause elongation or breakage of the Helix wire.

The study shows the follow-up of patients operated with helix wires.

PATIENTS AND METHODS

A retrospective study was carried out on the patients operated with dynamic Titanium Helix wires from June 2003 till June 2006. A total of 37 patients were included. Three patients were excluded because one died four weeks after surgery and two moved to another county and follow-up was not possible. A total of 34 patients were thus included in the study. There were 13 male and 21 female patients. Median age was 64 years (range : 22 to 89). The fractures were classified according to the Neer classification system for proximal humeral frac-

tures (4). Fractures included were 2 undisplaced, 30 Neer 2-fragment and 2 Neer 3-fragment displaced fractures. There were 2 high-energy and 32 low-energy fractures. Four patients had osteoporosis, 6 had multiple fractures and 9 had other significant systemic diseases. Patients were operated at an average of 2.5 days after trauma. During operation either 1 (18) or 2 (16) helix wires were used depending on stability of the fracture. Post operative immobilisation included 2-3 weeks in a fixed arm sling followed by 2-3 weeks of gradual movement in a collar and cuff. Flexion and abduction of more than 90° was not allowed in the first 5 weeks. Average duration of stay at hospital was 6.5 days, apart from one patient who had a complicated acetabular fracture. The first follow-up was at an average of 2.3 weeks and final follow-up at 14.8 weeks. Follow-up included both radiological and clinical assessment, and changing of fixed arm sling to collar and cuff.

Success was defined as radiological healing of the fracture. Failure was defined as secondary displacement of the fracture requiring further surgery, failure of implant or non-union.

RESULTS

Already at first follow-up 7 (20%) fractures were displaced, and further surgery was indicated. With follow-up at 14.8 weeks 9 more fractures were labelled as failures. In the failure group, apart from secondary displacement of fractures, complications included humeral head necrosis (2), non-union (3), biceps tendon rupture (2) and broken helix wire (3) (figs 1-4). The other fractures were healed radiologically and clinically. The end result was 16 (47%) failures and 18 (53%) successful cases. Further follow-up was not found necessary, as the end-result was achieved. Results are summarised in table I.

In the success group, an average of 80.5° flexion and 72° of abduction was achieved. Twelve patients had no or minimal pain, 2 had moderate pain and 4 had severe pain in the shoulder. In three patients, the indication for hemiarthroplasty was found due to severe pain and osteoarthritis.

DISCUSSION

The technique seemed promising at first, because of obvious benefits such as less surgery

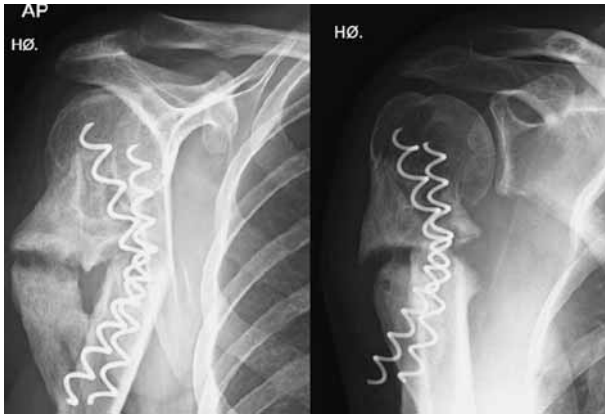


Fig. 1. — Non-union of a fracture of the proximal humerus after fixation with two helix wires.

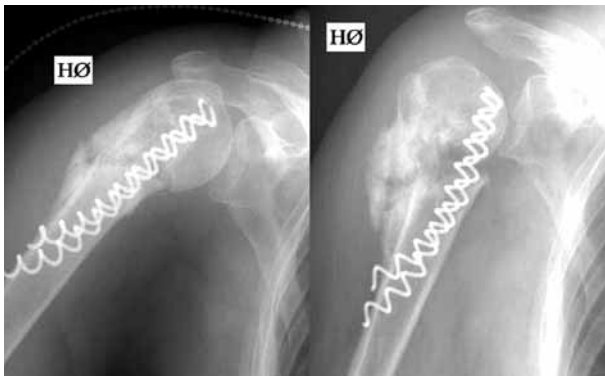


Fig. 2. — Non-union in another fracture, 5 months after internal fixation.

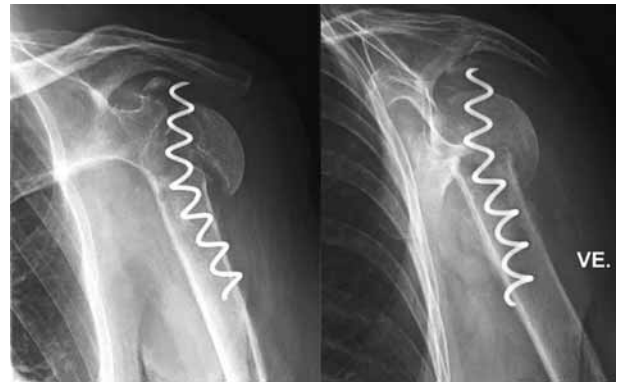


Fig. 3. — Humeral head necrosis, 4 months after operation

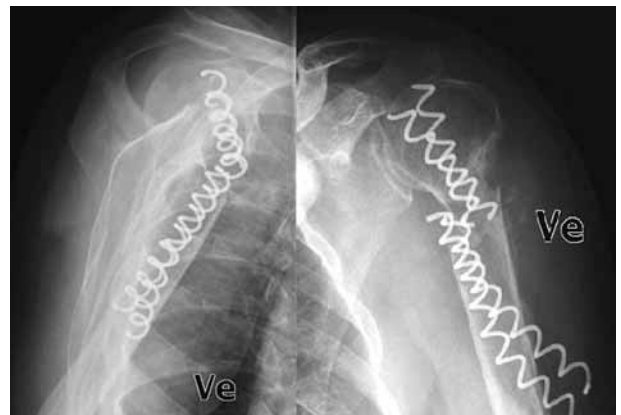


Fig. 4. — Breakage of implant, 3 months after operation

Table I. — Results

| | Type of fracture | | | Age (years) | |
|---------|------------------|------------|------------|-------------|----------|
| | Undisplaced | 2-fragment | 3-fragment | < 70 yrs | > 70 yrs |
| Success | 1 | 16 | 1 | 11 | 7 |
| Failure | 1 | 14 | 1 | 8 | 8 |

Total : Success : 18 (53%) ; failure : 16 (47%).

time required, easy approach and less soft tissue damage. But a failure rate of 47% overshadows the effectiveness of this method. In our retrospective study, we were unable to find any significant difference in results, with respect to patients' ages. Results were also similar whether one or two helix wires were used. Study by Raissadat *et al* (5) showed similar results with a non-union rate of

47%. Müller *et al* (3) found a 24% postoperative complication rate in 50 patients, with a postoperative revision rate of 18%.

The probable reason for the high failure rate with this technique is the flexible nature of the helix wire, as it does not prevent the fracture from displacing, and instead of micro-movements allows macro-movement, resulting in breakage of the

helix wire or non-union. We do not recommend this method as an optimal osteosynthesis of proximal humerus fractures.

REFERENCES

1. **Cosmi F, Martinelli B, Valentini R.** A mechanical and clinical evaluation of the Helix Wire for subcapital humerus fracture osteosynthesis. *Acta Bioeng Biomech* 2004 ; 6 : 3-12.
2. **Gorschewsky O, Peutz A, Klakow A.** The treatment of proximal humeral fractures with intramedullary titanium helix wire. *Arch Orthop Trauma Surg* 2005 ; 125 : 670-675.
3. **Müller F, Voithenleitner R, Schuster C et al.** [Operative treatment of proximal humeral fractures with helix wire.] (German). *Unfallchirurg* 2006 ; 109 : 1041-1047.
4. **Neer CS.** Displaced proximal humeral fractures : Part I. Classification and evaluation. *J Bone Joint Surg* 1970 ; 52-A : 1077-1089.
5. **Raissadat K, Struben PJ, van Loon CJ.** Helix wire osteosynthesis for proximal humeral fractures : unacceptable nonunion rate in two- and three-part fractures. *Arch Orthop Trauma Surg* 2004 ; 124 : 166-168.
6. **Traxler H, Surd R, Laminger KA et al.** Treatment of subcapital humeral fractures with dynamic helix wire and the risk of concomitant lesion of the axillary nerve. *Clin Anat* 2001 ; 14 : 418-423.