

# Pelvic Fractures: Part 1. Evaluation, Classification, and Resuscitation

Joshua R. Langford, MD  
Andrew R. Burgess, MD  
Frank A. Liporace, MD  
George J. Haidukewych, MD

## Abstract

Pelvic fractures range in severity from low-energy, generally benign lateral compression injuries to life-threatening, unstable fracture patterns. Initial management of severe pelvic fractures should follow Advanced Trauma Life Support protocols. Initial reduction of pelvic blood loss can be provided by binders, sheets, or some form of external fixation, which serve to reduce pelvic volume, stabilize clot formation, and reduce ongoing tissue damage. Persistently unstable patients may benefit from angiography with selective embolization, pelvic packing, or a combination of these interventions. Open pelvic fractures involving the perineum or bowel injury benefit from fecal diversion by colostomy. Trauma team coordination facilitates efficient resuscitative efforts and may affect definitive management by optimizing incision, ostomy, or catheter placement. Established protocols for both open and closed pelvic fractures help to standardize care.

Fractures of the pelvis can be a significant cause of patient morbidity and mortality. The spectrum of pelvic injuries ranges from low-energy pubic ramus fractures to high-energy unstable patterns that can result in massive hemorrhage and death. Timely, effective intervention can be lifesaving and may minimize long-term sequelae. Creation and execution of institutional protocols has proved to be helpful in delivering consistent care to patients with these injuries.<sup>1</sup>

An unstable pelvis can cause or contribute to hemodynamic instability because of vascular, visceral, or skeletal injury. Chronic pelvic instability can lead to debilitating pain and deformity. Orthopaedic surgeons managing pelvic fractures should have a clear understanding of the anatomy of the pelvis and be skilled in assessing and augmenting pelvic stability.

## Evaluation

The orthopaedic consultant who is called on to assess a patient with a pelvic fracture should begin with a history, including the mechanism of injury. Most pelvic fractures result from low-energy falls, but high-energy mechanisms such as highway motor vehicle collisions should alert the physician to the possibility of significant visceral injury, concomitant multisystem trauma, and hemorrhage. Such patients should be managed by a multidisciplinary trauma team according to the Advanced Trauma Life Support protocol.<sup>2</sup>

The pelvic evaluation should be part of a comprehensive musculoskeletal examination during the secondary survey. Position and symmetry of the lower extremities are noted, with attention paid to any

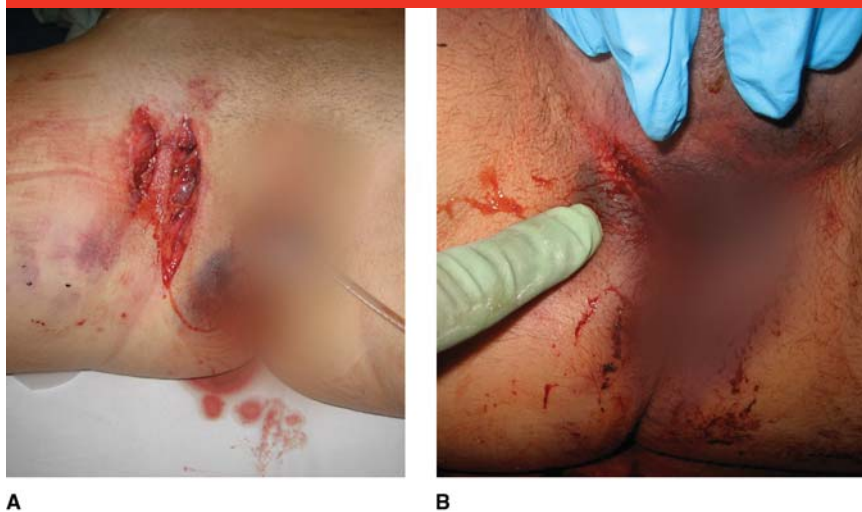
From the Orlando Regional Medical Center, Orlando, FL.

*J Am Acad Orthop Surg* 2013;21:448-457

<http://dx.doi.org/10.5435/JAAOS-21-08-448>

Copyright 2013 by the American Academy of Orthopaedic Surgeons.

Figure 1



**A and B,** Clinical photographs of perineal wounds after anteroposterior compression injury.

shortening and rotation of the leg. A circumferential examination of the skin is performed to seek open wounds, contusion, or degloving (ie, Morel-Lavallee lesion) and specifically to include the perineum (Figure 1). Urethral, scrotal, vaginal, rectal, and prostatic examinations are required, and any bleeding is noted. A detailed neurologic examination, including sensation, motor function, and reflexes, should be performed. All aspects of the examination should be concurrently recorded, including pertinent normal findings. In most cases, injuries to the urethra, genitalia, or rectum will trigger consultation with other specialists.

An initial AP pelvic radiograph is a routine part of the evaluation of high-energy blunt-trauma victims.

Suspicious or abnormal findings that suggest a pelvic fracture should be followed up with inlet and outlet radiographs and CT. The radiographic classification of the fracture will help guide risk assessment and initial treatment.

### Classification

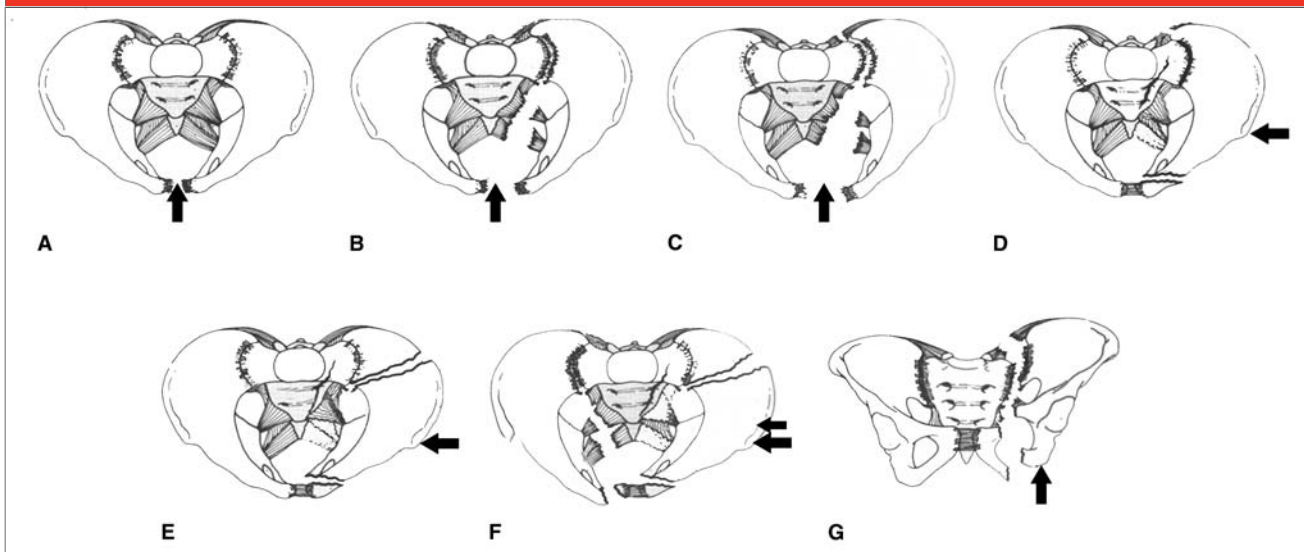
Various classification systems have been proposed to describe pelvic injuries. The Orthopaedic Trauma Association (OTA)/AO classification is based on degrees of rotational or translational displacement of the pelvic ring and has implications regarding the resultant instability. The OTA/AO classification is often used in research publications and may

have advantages in comparing studies in the literature. We generally prefer the Young-Burgess classification (Figure 2), derived from the early work of Tile and Pennal.<sup>3</sup> This system uses typical fracture patterns and displacements to infer the forces involved in creating the fracture and to predict which structures (particularly ligamentous) are damaged and have lost structural stability. This system has four categories: lateral compression (LC), anteroposterior compression (APC), vertical shear (VS), and combined mechanisms. LC and APC injuries have progressively numbered stages I through III, which represent increasing displacement and increasing injury.

The LC injury frequently results from side impact during a motor vehicle collision or a fall onto the side. An LC type I fracture often involves a buckle fracture of the sacral ala (Figure 3) in addition to pubic ramus fractures. Almost always the superior ramus fracture demonstrates a horizontal orientation on the radiograph, which is particularly well seen on the inlet view. LC type II injuries occur with further internal rotation of the hemipelvis and have a more nearly complete posterior disruption. There is frequently a fracture of the ilium, leaving a posterior “crescent” of bone, which remains attached by ligaments to the sacrum and L5 transverse process. LC type III injuries, often called a rollover or windswept pelvis, result from continued internal rotation of the injured iliac wing until the contralateral iliac wing begins

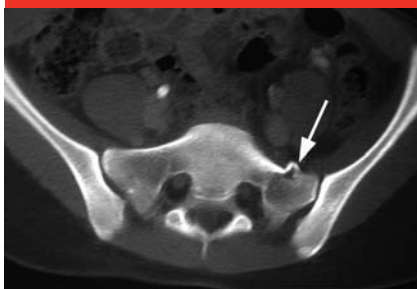Dr. Langford or an immediate family member serves as a paid consultant to Stryker and has stock or stock options held in the Institute for Better Bone Health, LLC. Dr. Burgess or an immediate family member is a member of a speakers' bureau or has made paid presentations on behalf of, and has stock or stock options held in, Stryker. Dr. Liporace or an immediate family member has received royalties from Biomet; is a member of a speakers' bureau or has made paid presentations on behalf of Biomet, Synthes, Stryker, and Medtronic; serves as a paid consultant to Biomet, Medtronic, Synthes, and Stryker; and serves as an unpaid consultant to AO. Dr. Haidukewych or an immediate family member has received royalties from DePuy and Biomet; serves as a paid consultant to Smith & Nephew, Synthes, and DePuy; has stock or stock options held in Orthopediatrics and the Institute for Better Bone Health; has received nonincome support (such as equipment or services), commercially derived honoraria, or other non-research-related funding (such as paid travel) from Synthes; and serves as a board member, owner, officer, or committee member of the American Academy of Orthopaedic Surgeons.

Figure 2



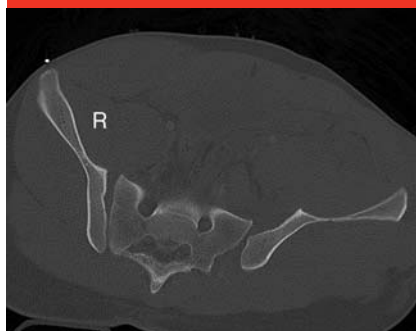The Young-Burgess classification of pelvic fracture. **A**, Anteroposterior compression (APC) type I. **B**, APC type II. **C**, APC type III. **D**, Lateral compression (LC) type I. **E**, LC type II. **F**, LC type III. **G**, Vertical shear. The arrow in each panel indicates the direction of force producing the fracture pattern. (Copyright Jesse B. Jupiter, MD, and Bruce D. Browner, MD.)

Figure 3



Axial CT scan demonstrating the lateral compression sacral injury pattern. Note the anterior sacral "buckle" (arrow).

Figure 4



Axial CT scan of anteroposterior compression type II (right sacroiliac joint) and type III (left sacroiliac joint) injuries.

to rotate externally, usually damaging the contralateral anterior (and occasionally, all) sacroiliac (SI) ligaments.

The APC type I injury is demonstrated by widening of the symphysis pubis without significant SI joint widening. Typically the diastasis of the pubic symphysis is <2.5 cm. It should be noted that the use of a single measurement alone to determine pelvic stability has been questioned

because recent literature has demonstrated that dynamic stress radiographs provide a more complete picture of global pelvic stability.<sup>4</sup> At least 40% of such injuries have some degree of recoil from the point of injury to the acquisition of the static radiograph.<sup>5</sup>

With greater external rotation of one or both halves of the pelvis, inju-

ries progress to APC type II. An APC type II injury is characterized by complete disruption of the pelvic floor ligaments (ie, sacrotuberous, sacrospinous) and anterior SI ligaments; however, the posterior SI ligaments remain intact. The SI joints are widened anteriorly, but the posterior aspects remain aligned.

APC type III injuries involve complete disruption of the posterior bony ligamentous system, with either a dissociated SI joint or a displaced, nonimpacted posterior fracture (Figure 4). The entire hemipelvis is unstable. Avulsion of the iliolumbar ligaments from the lumbar transverse processes may be seen.

VS injuries present with vertical displacement and usually involve complete disruption of the ligamentous attachment between the sacrum and the ilium posteriorly, although the vertical disruption may also occur through either the sacrum or the ilium. They often result from a fall from a height and are characterized

by complete instability of the iliac wing and cranial displacement of the ilium relative to the sacrum. Combined mechanism injuries are somewhat difficult to classify but commonly share features of many of the categories already mentioned.

The Young-Burgess classification has substantial intraobserver agreement and moderate interobserver agreement, which exceeds that of previous classification systems.<sup>6,7</sup> We find the Young-Burgess classification useful to assist in predicting resuscitative requirements and reconstructive decision making because of the understanding of the injured structures and the amount of energy that the pelvis has absorbed. For example, the APC injuries may be associated with bladder or urethral disruption, and the higher grades are associated with extensive blood loss resulting from disruption of vascular structures along with the pelvic floor ligaments. The horizontal fracture of the ramus associated with LC injuries creates a spike that may injure medial structures (ie, bladder, vagina, iliac arteries) when pushing through the pelvis. LC type I injuries rarely require surgical intervention; however, LC type II and III injuries are typically surgical candidates. Although all pelvic fractures can cause bleeding, instability, and visceral or neurovascular injury, awareness of fracture pattern and degree of displacement is helpful in risk assessment.

### Initial Management and Resuscitation

Provisional stabilization of the pelvic fracture can assist in control of hemorrhage and be an important part of patient resuscitation. In a patient with pelvic fracture and shock, it may be difficult to separate the hemorrhage resulting from the fracture

from hemorrhage resulting from injury to other structures, particularly intra-abdominal causes such as a ruptured spleen. In such cases, the findings on CT examination and the use of focused abdominal sonography for trauma or diagnostic peritoneal lavage may be useful. If such studies suggest multiple sources of bleeding, then careful coordination of care between specialists, based on predetermined protocols, is essential to optimize patient care. Priorities for coordinated care should be established by the trauma team in conference before patients need it. The protocol typically used at our institution for closed pelvic injury is summarized in Figure 5.

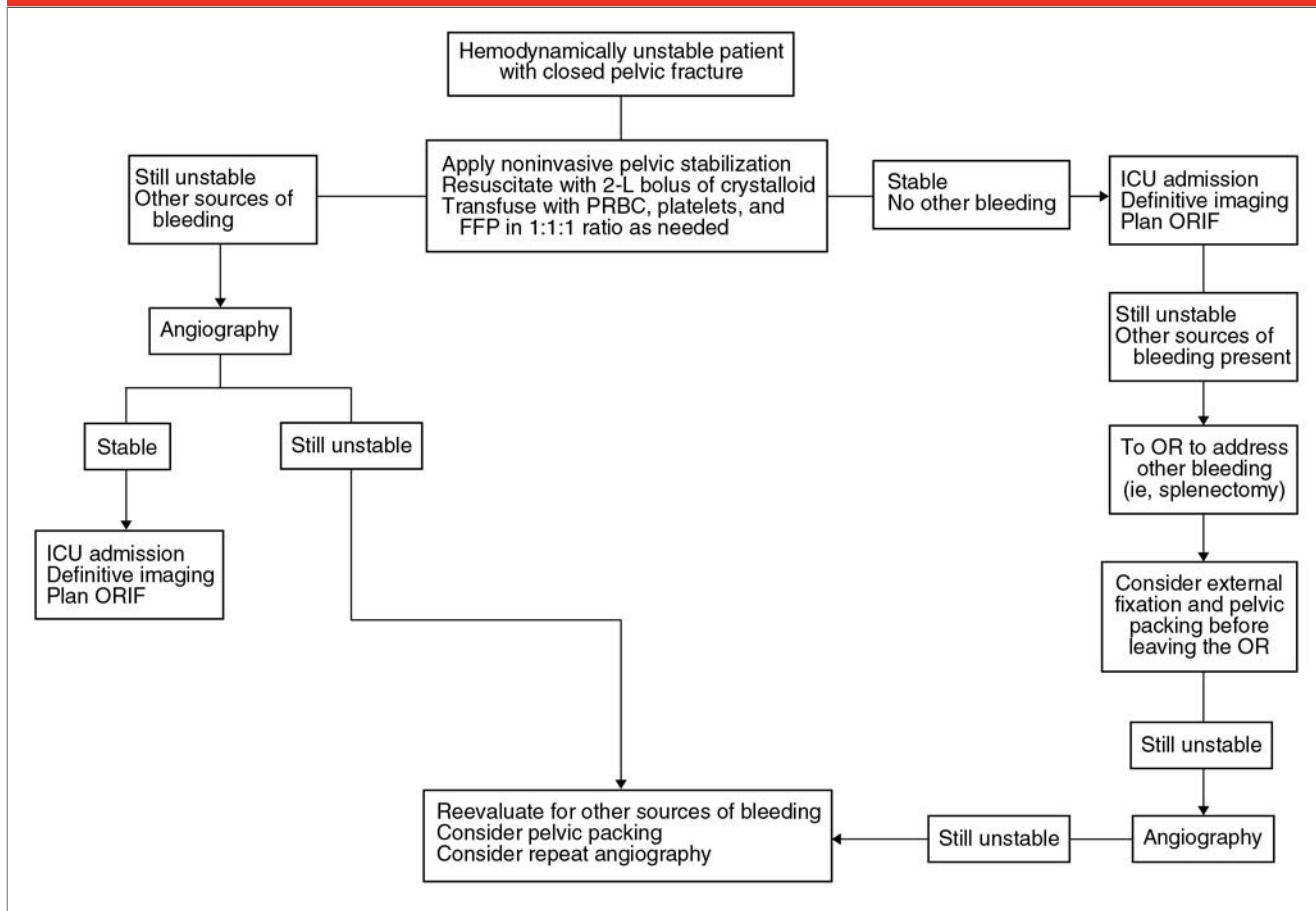
If no other source of bleeding is identified, the pelvic fracture should be addressed expeditiously. Management is initially provided by wrapping the pelvis with a compressive sheet or by use of a pelvic binder. Modalities that “close” the pelvic ring are sensible for injuries that open or externally rotate the ring. The AP pelvic radiograph will identify injuries that may benefit from this approach; generally LC injuries will not, whereas APC and VS injuries will. Compression of an LC injury is potentially damaging, although different imaging modalities demonstrate the difference in the pelvic position after applying a binder for a lateral compression injury (Figure 6). Occasionally, an LC injury in an elderly patient may have hemorrhage associated with vascular or visceral disruption; these patients will not benefit from wrapping or binding but may be candidates for angiography.

Closing the pelvic ring with a wrap or binder has some effect on pelvic volume but probably has a larger effect on stabilization of clots from bony surfaces and vascular structures.<sup>8,9</sup> Several commercial binders are available that facilitate placement

and adjustment of the compression applied (Figure 7, A and B). If a binder is not available, simple sheets can be used to wrap the pelvis. It is important to understand that these are temporizing measures to be utilized until more definitive fixation can be applied. The prolonged use of binders and sheets can lead to necrosis of underlying soft tissues and is not recommended.<sup>10</sup> The amount of time that the skin can tolerate the pressure of a sheet or binder without problematic breakdown has not been determined; however, in general, the sooner it is possible to perform some form of external or internal fixation and remove external skin pressure, the better.

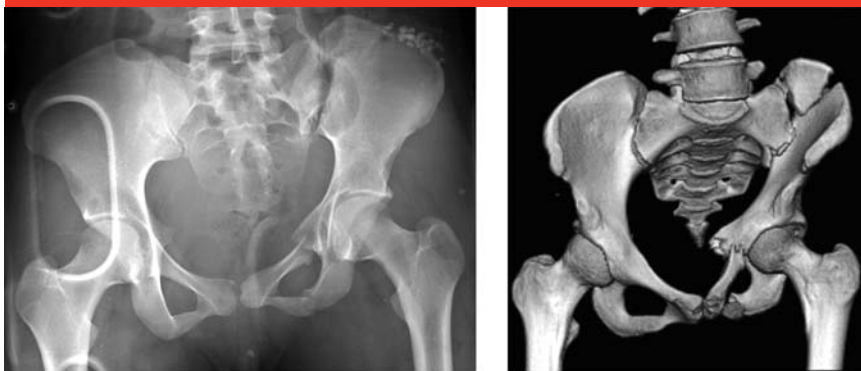The sheet or binder is applied at the level of the greater trochanters, never around the abdomen or waist, and should be flat against the skin to maximize surface area. Sheets should be secured with clamps to avoid undue pressure from knots.<sup>11</sup> Angiographic groin access, completion of a generous laparotomy distally, and similar anterior access issues can be addressed by cutting access portals in the binder or sheet or by compressing the pelvis indirectly by means of a secondary binder placed distally to the initial one on the thighs, combined with taping the knees and ankles together. This “multiple binder” method is preferred at our institution and may alleviate some concerns about soft-tissue problems from prolonged single-binder application (Figure 7, C). This method may also allow for a once-daily check of the skin overlying the greater trochanters by an experienced surgeon while maintaining general reduction. If notable vertical displacement exists (>1 cm) or notable flexion deformity is appreciated on screening radiographs, then skeletal traction can be a useful adjunct for initial stabilization. Traction can reduce displacement, add stability, improve hemo-

Figure 5



Algorithm for resuscitation of an unstable patient with a closed pelvic fracture. FFP = fresh frozen plasma, ICU = intensive care unit, OR = operating room, ORIF = open reduction and internal fixation, PRBC = packed red blood cells

Figure 6

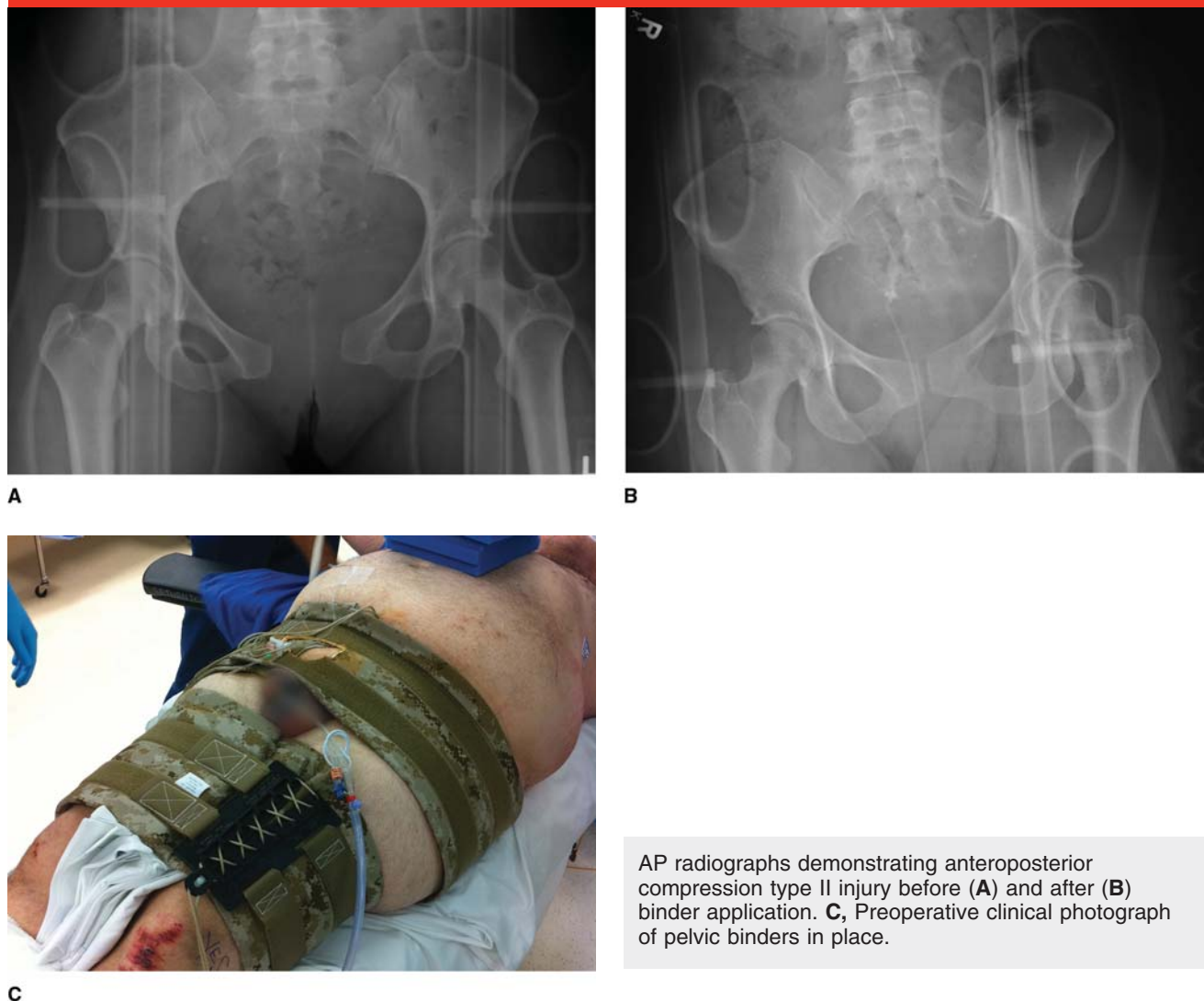


**A**, Presentation AP pelvic radiograph of a lateral compression type II pelvic injury. **B**, AP three-dimensional CT scan in the same patient after inappropriate use of a pelvic binder. Note accentuation of internal rotation deformity.

dynamics, and overcome deforming forces. Prior to application of distal femoral traction, it is important to confirm that the femur does not have a fracture or lesion and that its overlying soft tissue is intact.

When a patient requires emergent surgery for open wounds or intra-abdominal bleeding, pelvic stabilization may be accomplished by external fixation. External fixation, either with formal half pins or by some form of temporary pelvic C-clamp, can be useful in providing pelvic stability (Figure 8). Safe application of these devices requires knowledge of pelvic and neurovascular anatomy. With the ready availability of pelvic binders, the use of emergent external

Figure 7



AP radiographs demonstrating anteroposterior compression type II injury before (A) and after (B) binder application. C, Preoperative clinical photograph of pelvic binders in place.

fixation in the emergency department has decreased in many institutions. We do not recommend the use of so-called C-clamps applied in the trauma bay with blind pin placement, which can potentially injure intrapelvic neurovascular structures. Most trauma centers typically employ some form of pelvic binder and then later convert the patient to a more definitive form of pelvic fixation. Some military, blast-induced pelvic fractures have necessitated the return of the technique of iliac crest pin placement because of blast involvement with the anterior groin

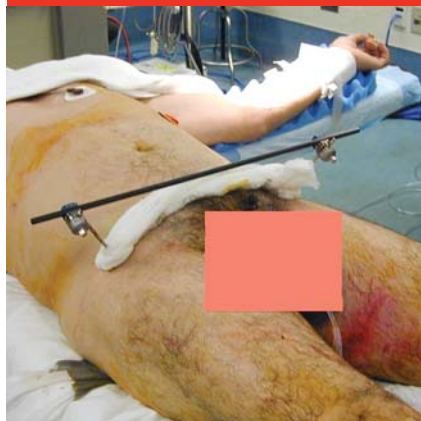and need for emergent stabilization in forward areas.

When other sources of bleeding have been ruled out, patients with persistent hemodynamic instability after control of the pelvic volume with binder or external fixation should be treated with angiography and selective embolization, or with pelvic packing, or both. These two methods address bleeding from different sources and should not always be thought of as competitive but rather as complementary methods of hemorrhage control.<sup>12</sup> Pelvic packing helps control bleeding from venous and bony sources, whereas ar-

teriography targets the 10% to 15% of patients who have bleeding from an arterial source.

The selection of technique may depend on the availability and ease of skilled arteriographers or on the patient's location. A patient who is already in the operating room because of visceral bleeding may not be appropriate for angiography until an intra-abdominal procedure is complete. Pelvic packing may be considered as a measure to improve hemostasis. If the patient remains persistently unstable after the thoracic and abdominal procedures and

Figure 8



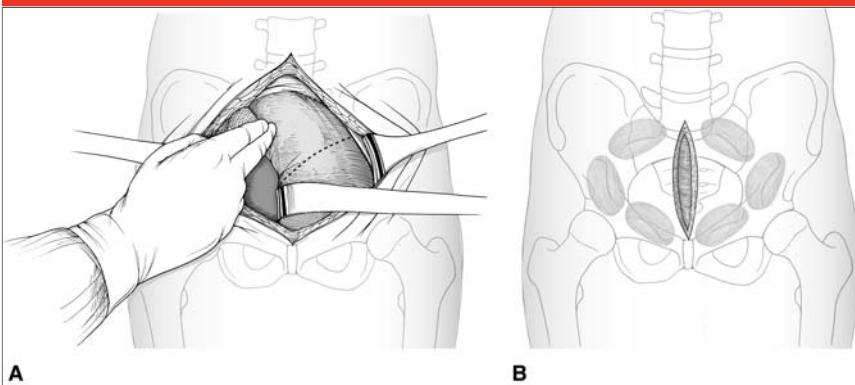
Postoperative photograph of pelvic external fixation in place using two supra-acetabular pins.

pelvic packing, then he or she may be transferred to angiography or undergo an intraoperative angiogram for further evaluation and treatment of persistent bleeding.

The concept of pelvic packing has been popular in several centers in the United States and Europe.<sup>13,14</sup> This procedure requires familiarity with the Pfannenstiel approach and knowledge of anatomy of the true pelvis to allow accurate pack placement. Retroperitoneal packing can avoid violating the intraperitoneal space and avoid unnecessary angiography (Figure 9). A recent study reported no mortality in hemodynamically unstable patients and only 16.7% need for subsequent angiographic embolization when this strategy was instituted.<sup>13</sup>

Angiography remains popular in the United States as a method to provide continued management of hemorrhage in the patient who is persistently or recurrently unstable after initial fluid and blood product resuscitation and management of pelvic volume. Evidence of contrast extravasation on trauma CT (Figure 10) can be considered an indication for angiography. If possible, selective embolization is generally preferred

Figure 9



Illustrations demonstrating the retroperitoneal packing technique. **A**, An 8-cm midline vertical incision is made. The bladder is retracted to one side, and three unfolded lap sponges are packed into the true pelvis (below the pelvic brim) with a forceps. The first is placed posteriorly, adjacent to the sacroiliac joint. The second is placed anterior to the first sponge at a point corresponding to the middle of the pelvic brim. The third sponge is placed in the retropubic space just deep and lateral to the bladder. The bladder is then retracted to the other side, and the process is repeated. **B**, Illustration demonstrating the general location of the six lap sponges following pelvic packing. (Adapted with permission from Smith WR, Moore EE, Osborn P, et al: Retroperitoneal packing as a resuscitation technique for hemodynamically unstable patients with pelvic fractures: Report of two representative cases and a description of technique. *J Trauma* 2005;59:1510-1514.)

(Figure 11) to prevent gluteal ischemia.<sup>15,16</sup> Minimization of gluteal ischemia is especially important if a later surgical approach is planned for that area. Recurrent pelvic bleeding has been reported after angiography and embolization in 8% to 23% of patients.<sup>17-19</sup> This fact emphasizes the importance of continued intensive care unit surveillance of these patients, even after a good initial response to resuscitation. A repeat angiographic embolization or even consideration of pelvic packing should be done if the patient has evidence of ongoing hemorrhage.

Both pelvic packing and angiography benefit from some form of stability having been imparted to the pelvic ring, either with binder or external fixation, and both have risks and disadvantages. A disadvantage of pelvic packing, other than the unfamiliarity with the surgical approach and technique by most ortho-

paedic surgeons, is the fact that it is an invasive procedure in a patient who can be quite unstable and coagulopathic. The packs typically need to be removed in several days and require an additional procedure for removal/exchange. Packing may also theoretically increase the risk of abdominal compartment syndrome.

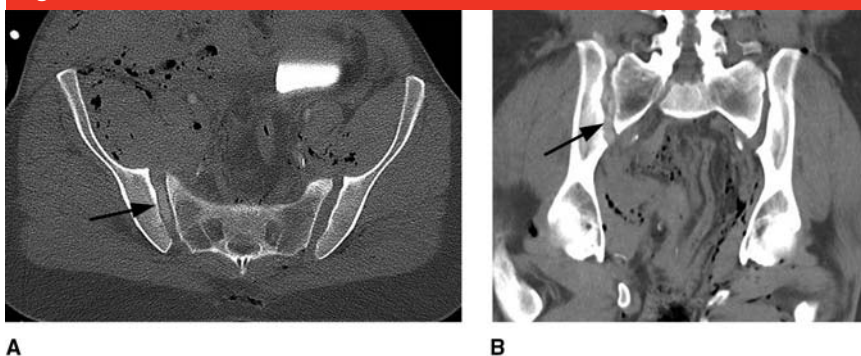
Allergies to the contrast dye, the need for the special expertise of an interventional radiologist, and ischemic complications from angiography may occur.<sup>15,16</sup> Angiography also takes time and resources and, in a patient who is quite unstable, may detract attention from injuries that require more emergent treatment.

### Open Pelvic Fracture

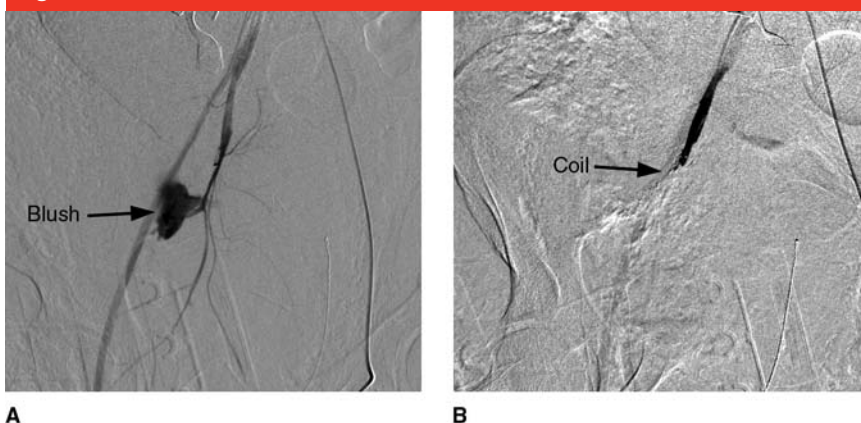
These injuries have more soft-tissue disruption and can lead to significant instability. Any potential tamponade

effect from controlling pelvic volume may be lost with larger wounds, and hemorrhage can be significant. Historically, open pelvic fractures have very high mortality rates because of hemorrhage and infection.<sup>20</sup> These patients almost always have other very serious sources of bleeding.<sup>21</sup> In the emergency department, the orthopaedic management includes packing, without exploration, of large open wounds exhibiting active bleeding and the application of non-invasive pelvic stabilization (ie, binder, sheet). After provisional pelvic stability has been achieved with an external fixator in the operating room, these wounds may be more formally explored and débrided. Colostomy for fecal diversion, particularly of open wounds involving the perineum, has substantially lowered mortality rates over recent years and should be considered. Colostomy is essential when there is exposed, necrotic, or perforated bowel.<sup>22,23</sup>

The protocol typically used at our institution for an open pelvic injury is summarized in Figure 12. Orthopaedic management of open pelvic injuries typically involves irrigation and débridement of any open wounds, packing, and concomitant pelvic external fixation. Although placement of an external fixator will provide some stability, it will not achieve complete tamponade. Direct packing of the open wound or wounds and selective angiography with selective embolization should be considered. Vaginal, rectal, and genital wounds obviously should be managed expeditiously in concert with the appropriate subspecialties. Collaboration with the associated subspecialties helps with the placement of diverting colostomies and of suprapubic tubes placed as far as possible from planned surgical incisions used to definitively treat the pelvic ring injury to decrease potential infections. Broad-spectrum anti-

**Figure 10**

Axial (A) and coronal (B) CT scans demonstrating contrast extravasation (arrows) into the right sacroiliac joint.

**Figure 11**

Arteriograms demonstrating angiographic blush before (A) and after (B) coil embolization.

biotics are indicated as part of the initial management because visceral and urogenital injuries, as well as late infectious complications, are common. When concerns regarding contamination exist, wounds should be packed open until repeat evaluation has deemed them stable without further declaration of necrosis. On wound closure, we recommend the use of deep drains.

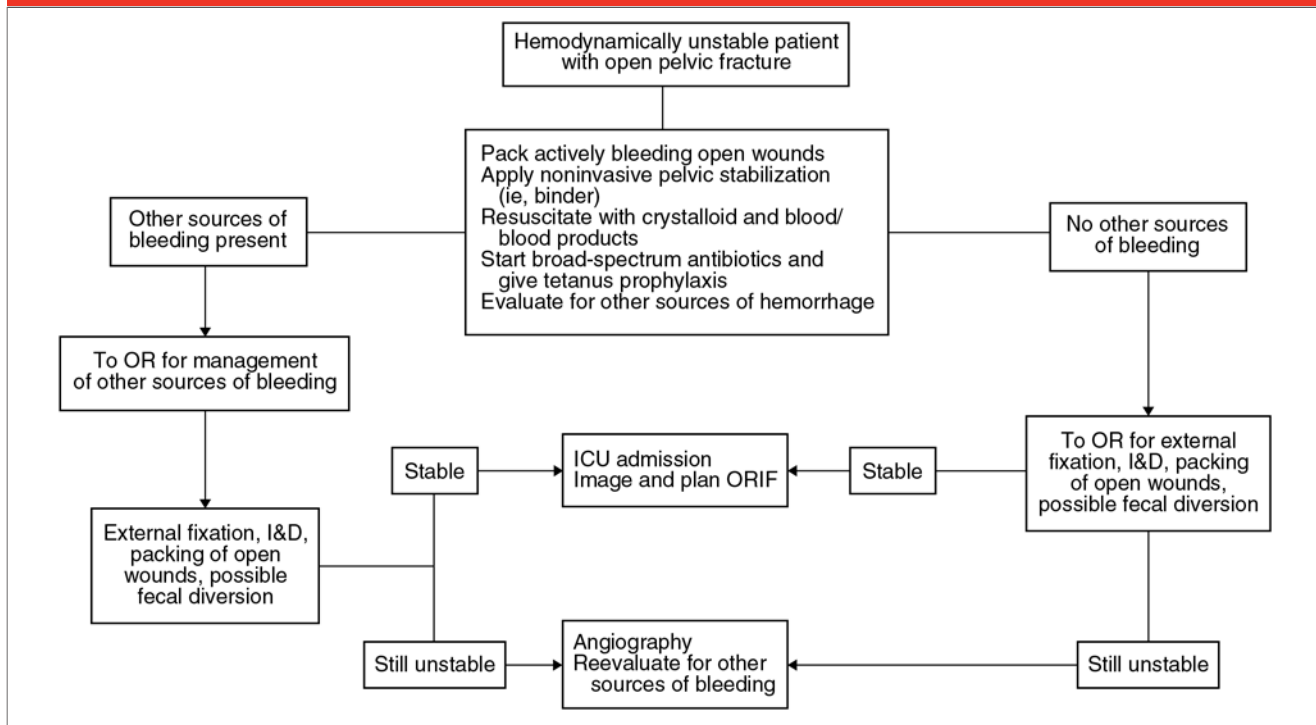
### Summary

Pelvic fractures range from low-energy, generally benign pubic ramus lateral compression injuries to high-

energy, life-threatening, unstable fracture patterns. High-energy mechanisms of injury indicate the possibility of significant visceral injury, multisystem trauma, and hemorrhage. The Young-Burgess classification of LC, APC, VS, and combined mechanisms assists in predicting resuscitative requirements and reconstructive decision making. Initial reduction of pelvic blood loss is provided by binders, sheets, or another form of external fixation, which reduces pelvic volume, stabilizes clot formation, and reduces ongoing tissue damage. Persistently unstable patients may benefit from angiography with selec-



Figure 12



Algorithm for resuscitation of an unstable patient with an open pelvic fracture. ICU = intensive care unit, I&D = irrigation and débridement, OR = operating room, ORIF = open reduction and internal fixation

tive embolization, pelvic packing, or a combination of these two. Open pelvic fractures involving the perineum or bowel injury benefit from fecal diversion by colostomy.

## References

*Evidence-based Medicine:* Levels of evidence are described in the table of contents. In this article, references 4 and 9 are level II studies. References 1, 6, 7, 10, 17-19, 22, and 23 are level III studies. References 11, 13-16, and 21 are level IV studies. References 12 and 20 are level V expert opinion.

References printed in **bold type** are those published within the past 5 years.

1. Osborn PM, Smith WR, Moore EE, et al: **Direct retroperitoneal pelvic packing versus pelvic angiography: A comparison of two management protocols for haemodynamically unstable pelvic fractures.** *Injury* 2009;40(1):54-60.

2. American College of Surgeons: *Advanced Trauma Life Support Manual*, ed 8. Chicago, IL, American College of Surgeons, 2008, p 366.
3. Tile M, Pennell GF: Pelvic disruption: Principles of management. *Clin Orthop Relat Res* 1980;151:56-64.
4. Sagi HC, Coniglione FM, Stanford JH: Examination under anesthetic for occult pelvic ring instability. *J Orthop Trauma* 2011;25(9):529-536.
5. Gardner MJ, Krieg JC, Simpson TS, Bottlang M: Displacement after simulated pelvic ring injuries: A cadaveric model of recoil. *J Trauma* 2010;68(1):159-165.
6. Furey AJ, O'Toole RV, Nascone JW, Sciadini MF, Copeland CE, Turen C: Classification of pelvic fractures: Analysis of inter- and intraobserver variability using the Young-Burgess and Tile classification systems. *Orthopedics* 2009;32(6):401.
7. Koo H, Leveridge M, Thompson C, et al: Interobserver reliability of the Young-Burgess and Tile classification systems for fractures of the pelvic ring. *J Orthop Trauma* 2008;22(6):379-384.
8. Bottlang M, Krieg JC, Mohr M, Simpson TS, Madey SM: Emergent management of pelvic ring fractures with use of circumferential compression. *J Bone Joint Surg Am* 2002;84(suppl 2):43-47.
9. Krieg JC, Mohr M, Ellis TJ, Simpson TS, Madey SM, Bottlang M: Emergent stabilization of pelvic ring injuries by controlled circumferential compression: A clinical trial. *J Trauma* 2005;59(3):659-664.
10. Spanjersberg WR, Knops SP, Schep NW, van Lieshout EM, Patka P, Schipper IB: Effectiveness and complications of pelvic circumferential compression devices in patients with unstable pelvic fractures: A systematic review of literature. *Injury* 2009;40(10):1031-1035.
11. Rouff ML Jr, Falicov A, Woodhouse E, Schildhauer TA: Circumferential pelvic antishock sheeting: A temporary resuscitation aid. *J Orthop Trauma* 2006;20(1 suppl):S3-S6.
12. Suzuki T, Smith WR, Moore EE: Pelvic packing or angiography: Competitive or complementary? *Injury* 2009;40(4):343-353.
13. Cothren CC, Osborn PM, Moore EE, Morgan SJ, Johnson JL, Smith WR: Preperitoneal pelvic packing for hemodynamically unstable pelvic fractures: A paradigm shift. *J Trauma* 2007;62(4):834-842.

14. Burlew CC, Moore EE, Smith WR, et al: Preperitoneal pelvic packing/external fixation with secondary angioembolization: Optimal care for life-threatening hemorrhage from unstable pelvic fractures. *J Am Coll Surg* 2011; 212(4):628-637.
15. Suzuki T, Shindo M, Kataoka Y, et al: Clinical characteristics of pelvic fracture patients with gluteal necrosis resulting from transcatheter arterial embolization. *Arch Orthop Trauma Surg* 2005;125(7): 448-452.
16. Yasumura K, Ikegami K, Kamohara T, Nohara Y: High incidence of ischemic necrosis of the gluteal muscle after transcatheter angiographic embolization for severe pelvic fracture. *J Trauma* 2005;58(5):985-990.
17. Fang JF, Shih LY, Wong YC, Lin BC, Hsu YP: Repeat transcatheter arterial embolization for the management of pelvic arterial hemorrhage. *J Trauma* 2009;66(2):429-435.
18. Gourlay D, Hoffer E, Routt M, Bulger E: Pelvic angiography for recurrent traumatic pelvic arterial hemorrhage. *J Trauma* 2005;59(5):1168-1174.
19. Shapiro M, McDonald AA, Knight D, Johannigman JA, Cuschieri J: The role of repeat angiography in the management of pelvic fractures. *J Trauma* 2005;58(2): 227-231.
20. Grotz MR, Allami MK, Harwood P, Pape HC, Krettek C, Giannoudis PV: Open pelvic fractures: Epidemiology, current concepts of management and outcome. *Injury* 2005;36(1):1-13.
21. Dente CJ, Feliciano DV, Rozycki GS, et al: The outcome of open pelvic fractures in the modern era. *Am J Surg* 2005;190(6):830-835.
22. Jones AL, Powell JN, Kellam JF, McCormack RG, Dust W, Wimmer P: Open pelvic fractures: A multicenter retrospective analysis. *Orthop Clin North Am* 1997;28(3):345-350.
23. Pell M, Flynn WJ Jr, Seibel RW: Is colostomy always necessary in the treatment of open pelvic fractures? *J Trauma* 1998;45(2):371-373.