

3 Surgical approach

The old incision over the dorsal ulna is opened using the interval between extensor and flexor carpi ulnaris.

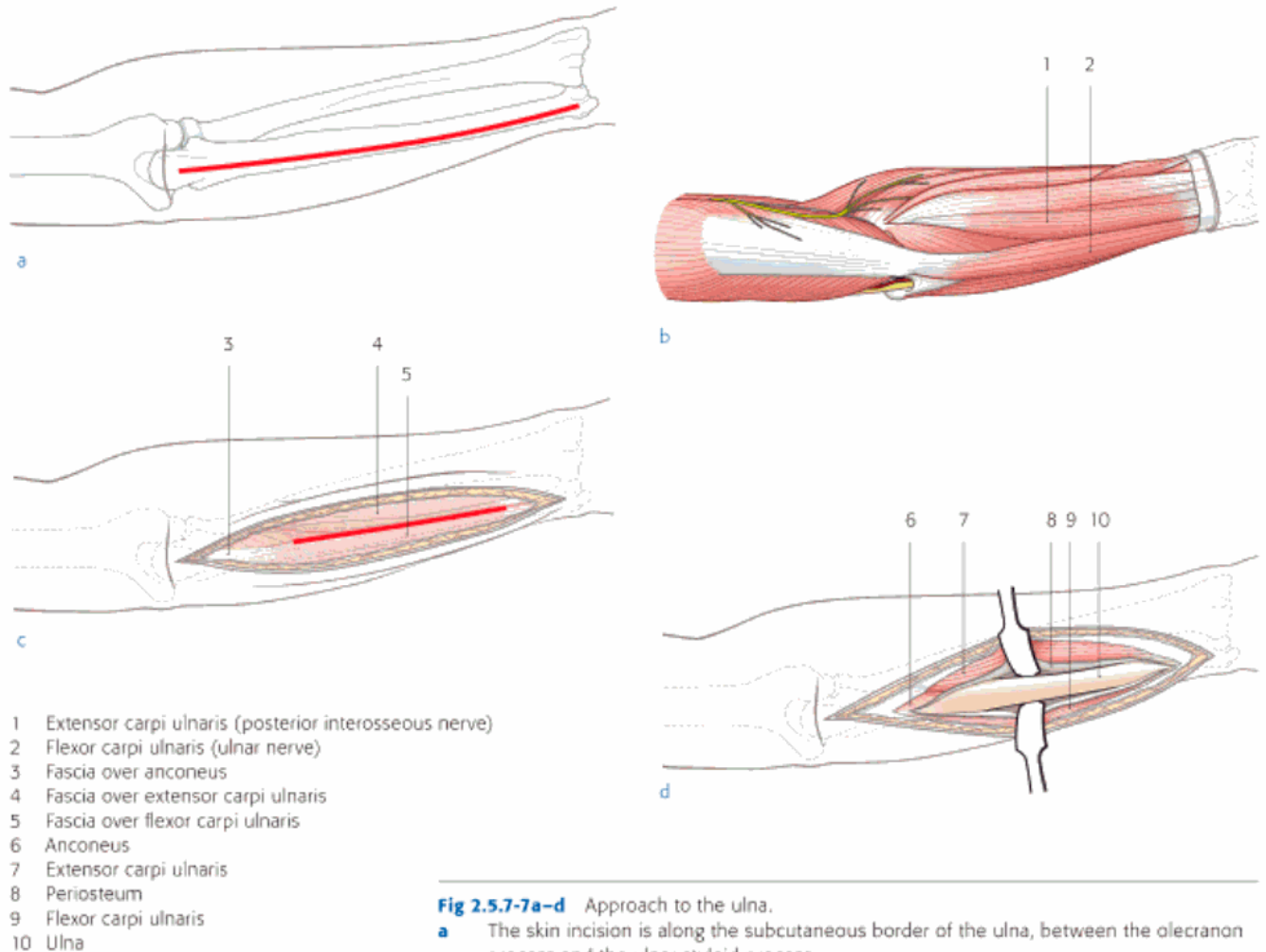


Fig 2.5.7a-d Approach to the ulna.

- a** The skin incision is along the subcutaneous border of the ulna, between the olecranon process and the ulnar styloid process.
- b-c** The dissection should be carried out between the flexor carpi ulnaris and the extensor carpi ulnaris muscles. The internervous plane is between the ulnar and posterior interosseous nerves.
- d** According to the position and length of the plate, a delicate detachment of muscles from the periosteum is performed.